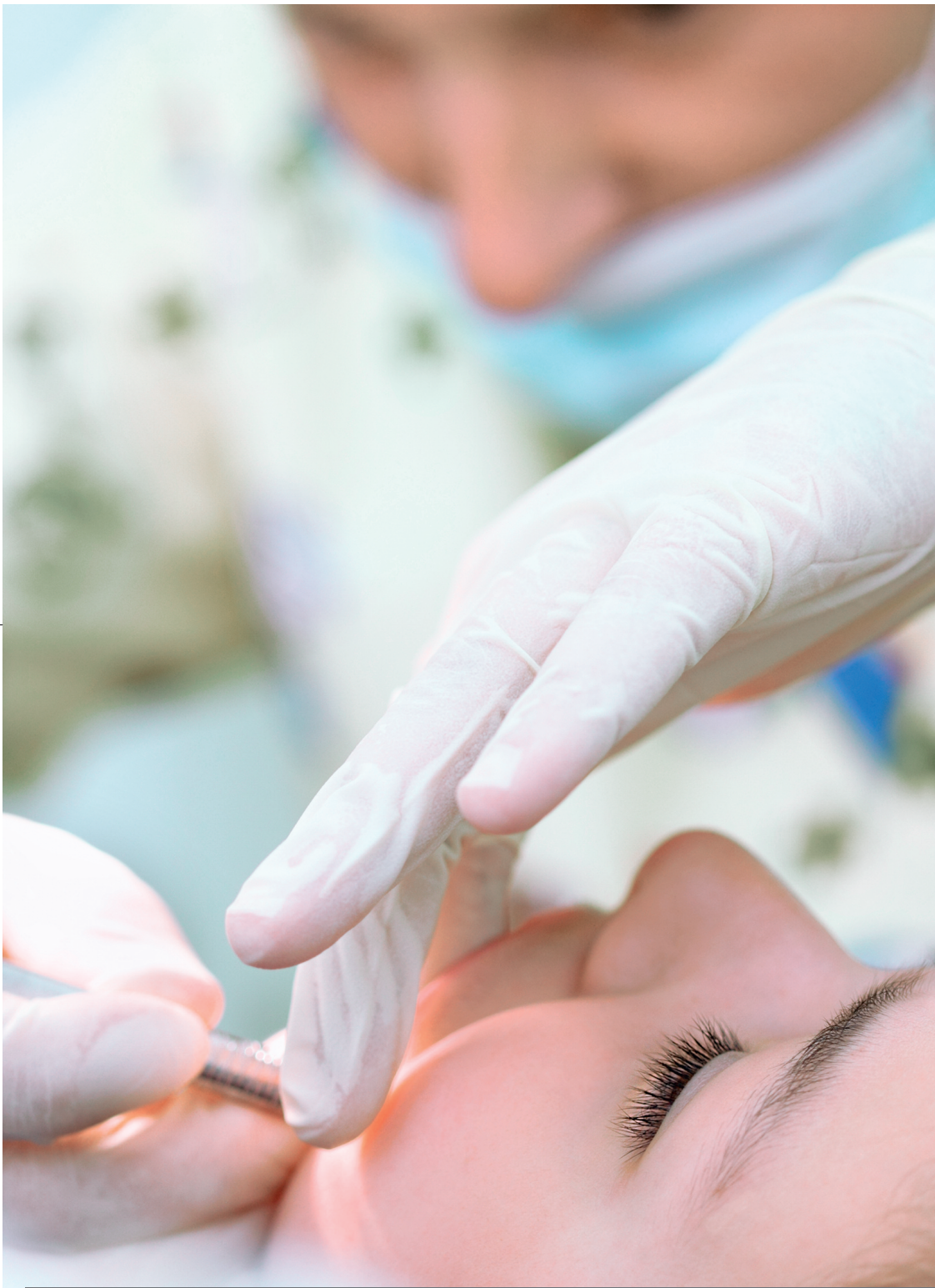

# Septodont Case Studies

No. 11 - June 2015

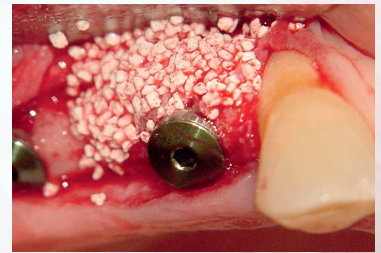
## Collection



### R.T.R.

Sinus floor augmentation

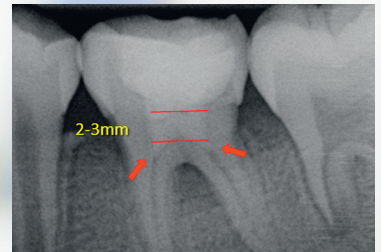
M.E. García-Briseño



### BIODENTINE™

Pulpotomy on a 6-year molar

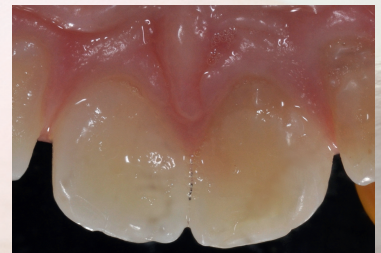L. Martens / R. Cauwels



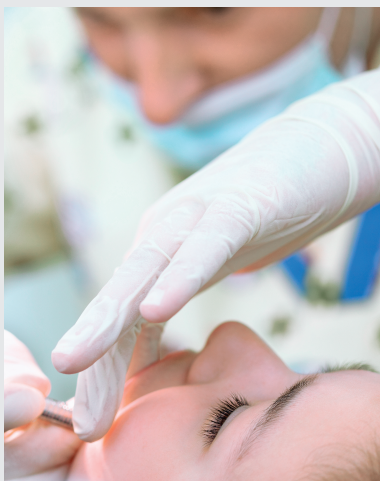### BIODENTINE™

Apexogenesis

R. Cauwels / L. Martens



# Editorial



© Pana, J. Dreamstime

Since its foundation Septodont has developed, manufactured and distributed a wide range of high quality products for dental professionals.

Septodont recently innovated in the field of gingival preparation, composites and dentine care with the introduction of Racegel, the N'Durance® line and Biodentine™, which are appreciated by clinicians around the globe.

Septodont created the “*Septodont Case Studies Collection*” - a series of case reports - in 2012 to share with you their experience and the benefits of using these innovations in daily practice.

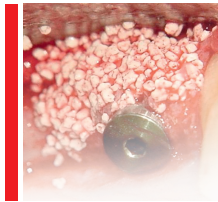
Over the past 3 years, authors from more than 15 countries have generously contributed to the success of our magazine that is now distributed on the 5 continents.

Each new issue of the Case Studies Collection is the opportunity to discover new clinical challenges and their treatment solutions.

This 11th issue is dedicated to two of Septodont's innovative products:

- R.T.R., an easy-to-use synthetic bone grafting material. In addition to its ability to provide an optimal osteoconductive environment to promote the growth of new dense bone, R.T.R. comes in 3 different presentations to suit all the clinical situations.
- Biodentine™, the first biocompatible and bioactive dentin replacement material. Biodentine™ uniqueness not only lies in its innovative bioactive and “pulp-protective” chemistry, but also in its universal application, both in the crown and in the root.

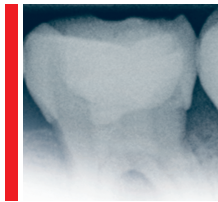
# Content



## Sinus Floor Augmentation with $\beta$ -Tricalcium Phosphate (R.T.R. Septodont)

04

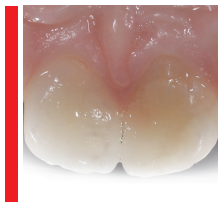
Mario Ernesto García-Briseño



## Biodentine™ - Pulpotomy on a 6-year molar

11

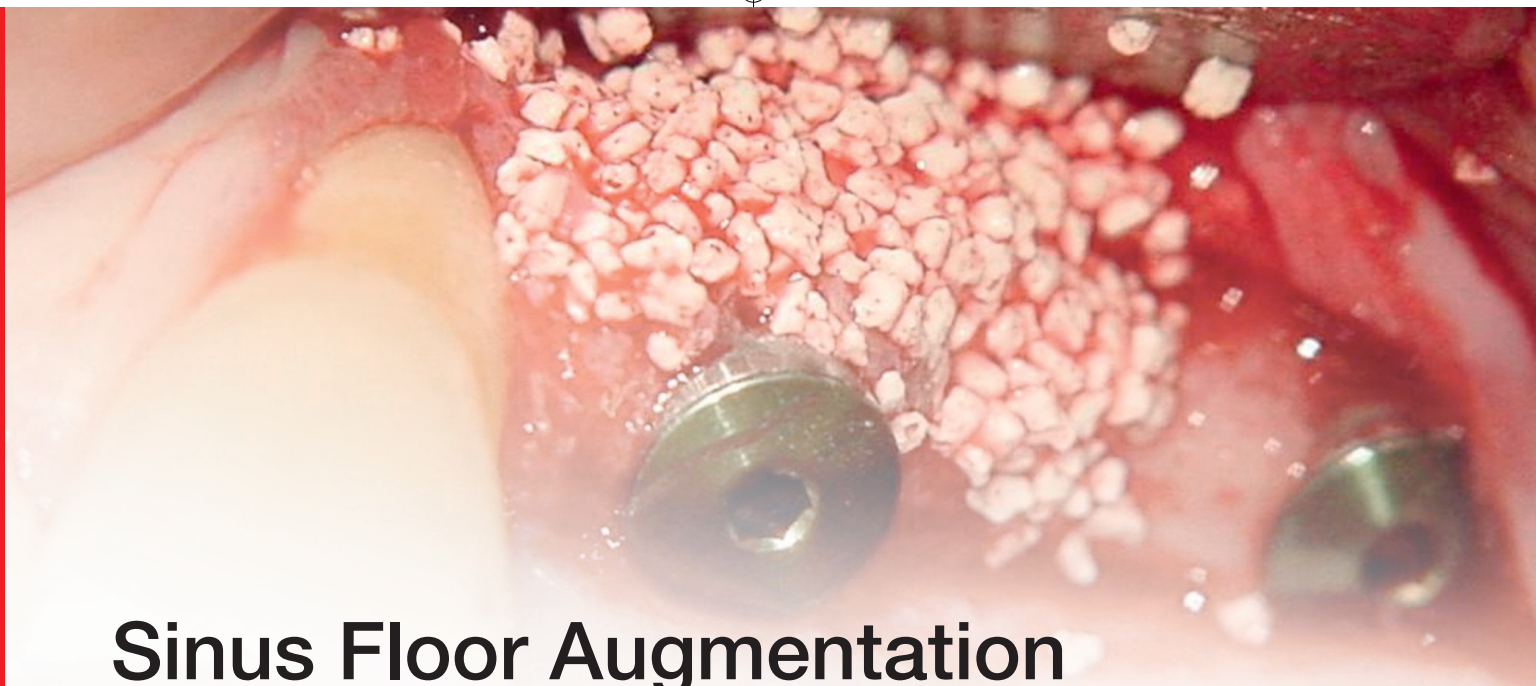
Luc Martens  
Rita Cauwels



## Biodentine™ - Apexogenesis

15

Rita Cauwels  
Luc Martens



# Sinus Floor Augmentation with $\beta$ -Tricalcium Phosphate (R.T.R. Septodont)

Mario Ernesto García-Briseño

DDS and Professor in Periodontics - Autonomous University of Guadalajara (UAG), Mexico

Resorption of the alveolar process and pneumatization of sinus in the edentulous posterior maxilla are a clinical challenge in the restorative/prosthetic treatment with dental implants. Diverse surgical procedures, bone grafts and substitutes have been used to repair that clinical situations. Reports have shown radiographic, histomorphometric and clinical significant results with  $\beta$ -Tricalcium Phosphate. Two clinical cases of sinus floor augmentation with  $\beta$ -Tricalcium Phosphate (R.T.R. Septodont) or the subsequent insertion of dental implant are presented in this report.

## History

Resorption of the alveolar process and the pneumatization of the sinus in the posterior edentulous maxilla often represents a clinical challenge in restorative/prosthetic treatment with dental implants (1).

Al-Nawas and Schiegnitz (2014), continuing the work of Klein (3), have proposed a classification of augmentation procedures in which graft materials are used for bone formation in therapy with dental implants:

1) Maxillary sinus floor augmentation, including the lateral window technique and transalveolar approach and, 2) vertical and/or lateral alveolar ridge augmentation, including dehiscence-type and/or fenestration-type defect around the implant (2).

The biological and physiological properties of the bone grafts and bone substitute materials

(BSM) have been described in terms of osteoinductivity, osteoconductivity and osteogenicity. Osteoconductivity can be described in terms of a biocompatible scaffold, resorbable at different speeds and time, in which the material reacts without consequences with the tissues at the receptor site. The three-dimensional structure of the material mostly facilitates vascular proliferation and, soon after, colonization and growth of osteoprogenitor and osteogenic cells. The physical and chemical properties influence bone formation to a lesser degree (4).

## Tricalcium Phosphate

With a composition and crystallinity similar to the mineral phase of bone, Tricalcium Phosphate ( $\text{Ca}_3(\text{PO}_4)_2$ ) is a biocompatible and bioresorbable material. Biodegradation of the material occurs in two ways: dissolution and osteoclastic resorp-

tion (5). Animal models have shown the resorption of beta-TCP, its replacement by bone and formation of bone marrow (6). Particle size, microporosity and speed of resorption confer its osteoconductive properties and promote the bone formation process (7, 8). Placed directly in cancellous bone, it retains its osteoconductive properties, and no tissue or systemic reactions were reported (9). Osteoconductive properties have been reported at ectopic sites (10). For decades, it has been used in Orthopaedics and multiple dental applications (11-14).

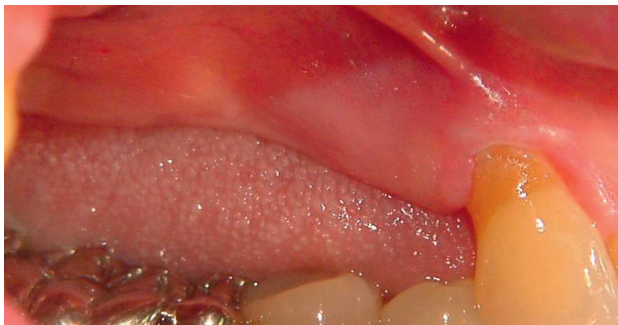### Procedure for maxillary sinus floor elevation

Two authors developed the surgical technique to augment bone height from the base of the maxillary floor (15, 16). Various modifications have been reported in the literature, but retaining the initial proposal: increasing the vertical dimension from

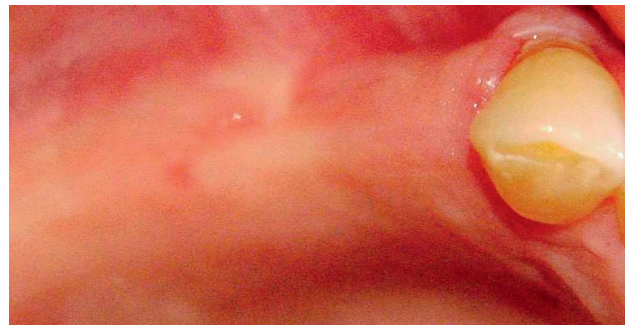the maxillary sinus floor with the use of graft and/or bone substitute materials placed between detached epithelial membrane and the denuded bone (17, 18, 24). The use of bone substitute materials has been reported in maxillary sinus floor augmentation procedures (19), including beta-tricalcium phosphate (20-22), with histomorphometric analysis (23) and simplified techniques (24). Trombelli et al. (2014) report the results of transcrestal maxillary sinus floor elevation done with a minimally invasive procedure and combined with the additional use of deproteinized bovine bone mineral or beta-tricalcium phosphate. (24) The survival of dental implants in maxillary sinus floor augmentation procedures with  $\beta$ -tricalcium phosphate has been reported. (1) The authors report an increase in bone quantity associated with a decrease in grafted material and the presence of osteoclasts around the remaining particles of material. No complications or loss of implants were reported at 12 months.

## Case Report no.1

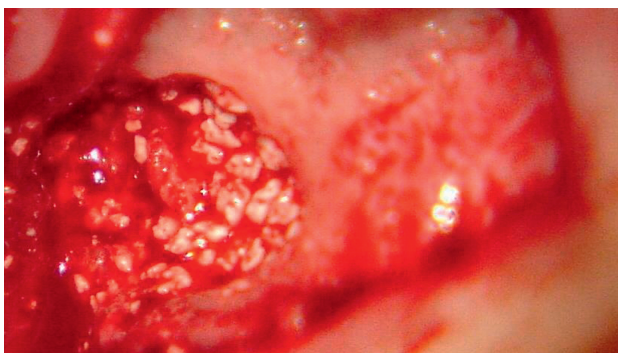
### Female patient, 56 years of age



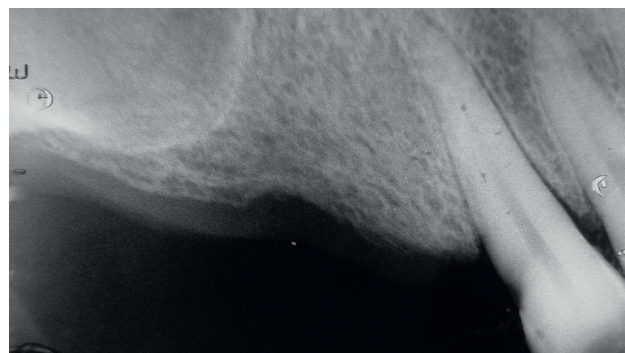
*Fig. 1:* Edentulous area, first quadrant. Absence of premolars and molars lost 12 years ago. Replaced with removable partial denture.



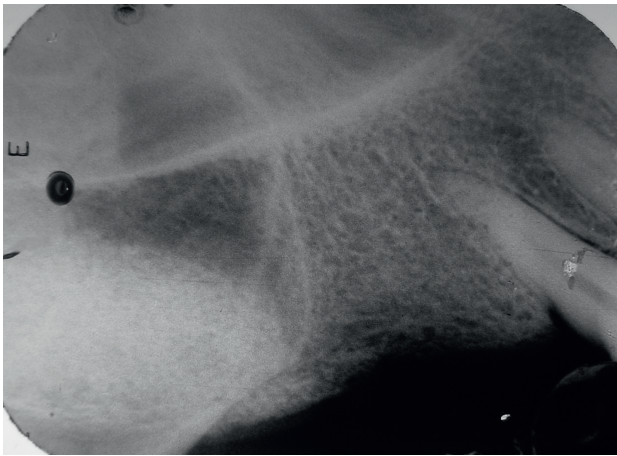
*Fig. 2:* Occlusal view, quadrant 1.



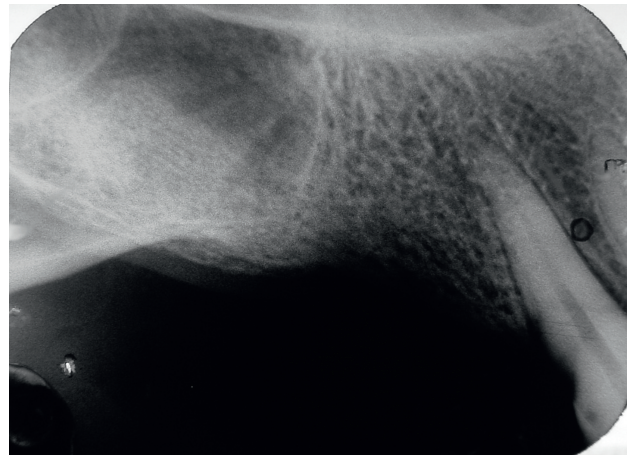
*Fig. 3:* Maxillary sinus floor augmentation procedure with lateral approach and  $\beta$ -Tricalcium Phosphate "R.T.R." Septodont with bone graft substitute material (day 0).



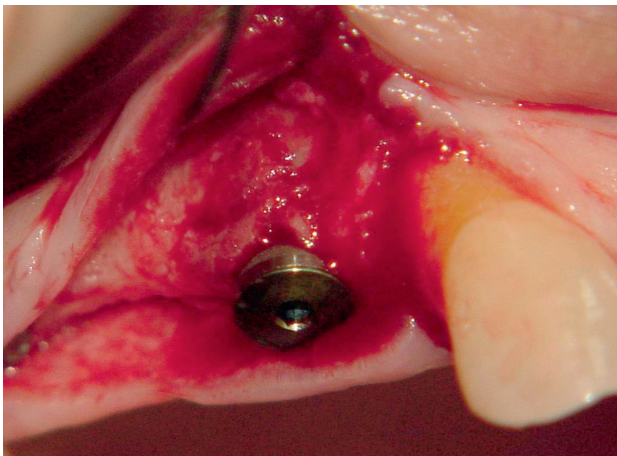
*Fig. 4:* Pre-op X-ray (day 0).



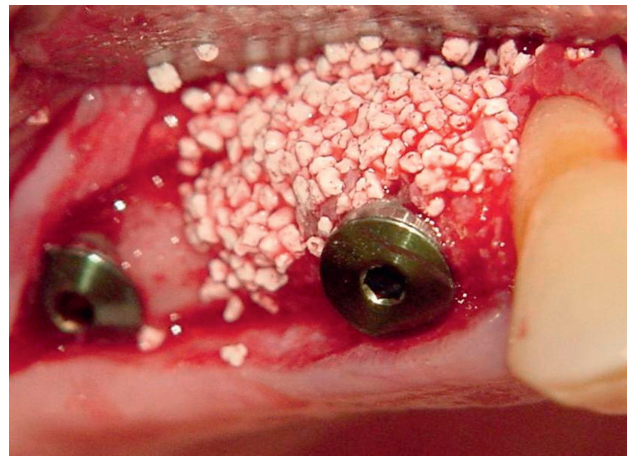**Fig. 5:** X-ray immediately post-op showing the location of the  $\beta$ -Tricalcium Phosphate on the maxillary sinus floor -radiolucent area- (day 0).



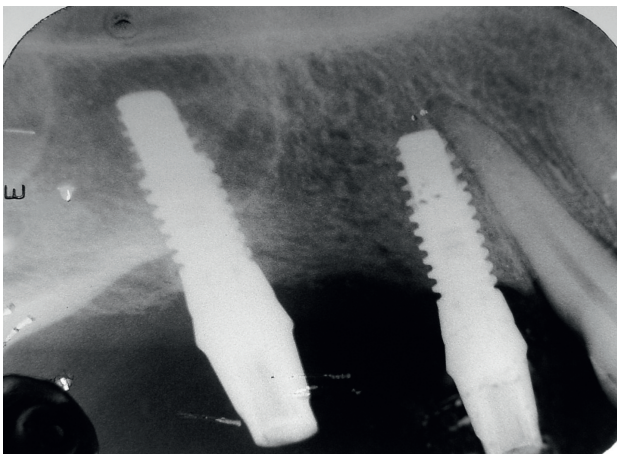
**Fig. 6:** X-ray six months after the maxillary sinus floor augmentation procedure with lateral approach and  $\beta$ -Tricalcium Phosphate "R.T.R." Septodont as bone graft substitute material. The decrease in the radiolucent area shown in Fig. 6 is obvious, indicating the replacement of the material with new bone.



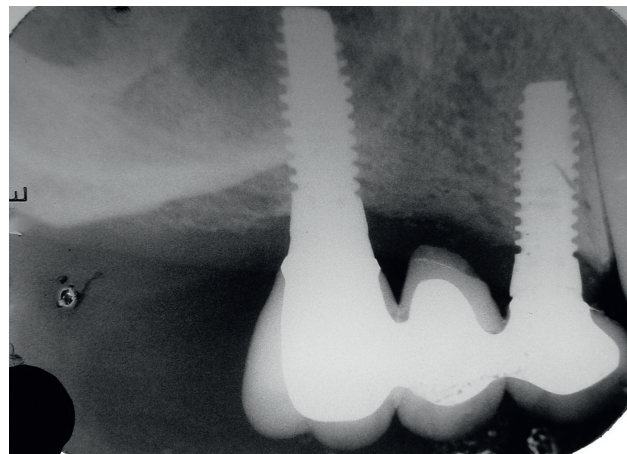
**Fig. 7:** During the surgical procedure (at 7 months) of implant placement, at the site of 14, the presence of the vestibular cortical plate of inadequate thickness is noted.



**Fig. 8:**  $\beta$ -Tricalcium Phosphate "R.T.R." Septodont as bone graft substitute material in the vestibular plate of 14. Distal implant in the first molar area placed in the area of the maxillary sinus floor augmented 7 months earlier.



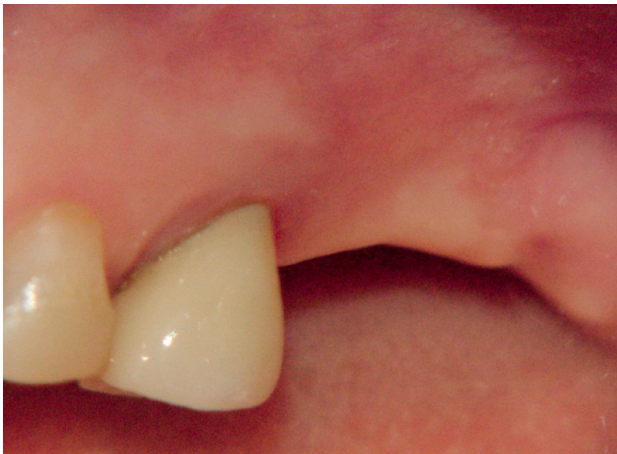**Fig. 9:** X-ray immediately after placement of the prosthetic pillars on the implants. Stability of the implant in the area of 16 was clinically proven.



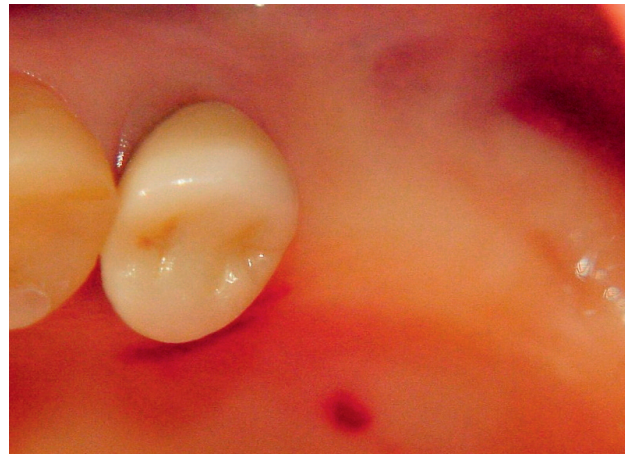
**Fig. 10:** Prosthetic restoration 10 months after the maxillary sinus floor augmentation procedure with lateral approach and  $\beta$ -Tricalcium Phosphate "R.T.R." Septodont and 3 months after placement of the implants.

# Case Report no.2

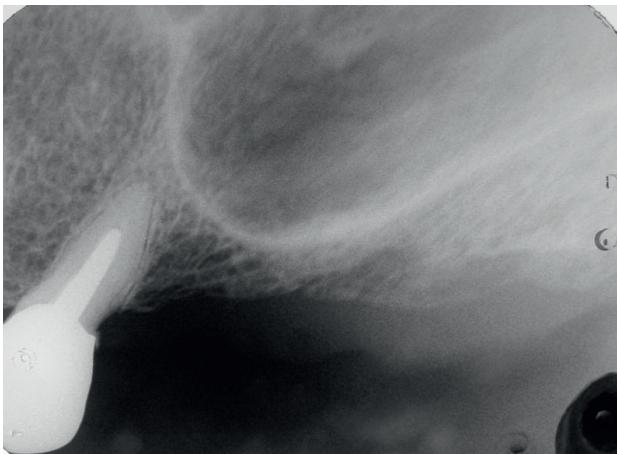
Female patient, 55 years of age



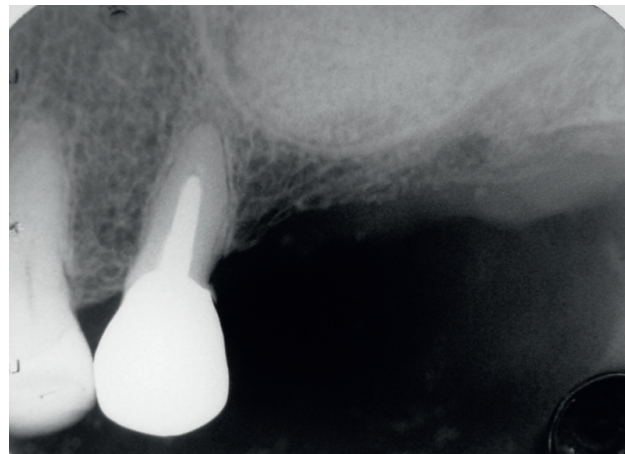
*Fig. 1:* Left atrophic posterior maxilla. Absence of molars lost approx. 10 years ago. Replaced with removable partial denture.



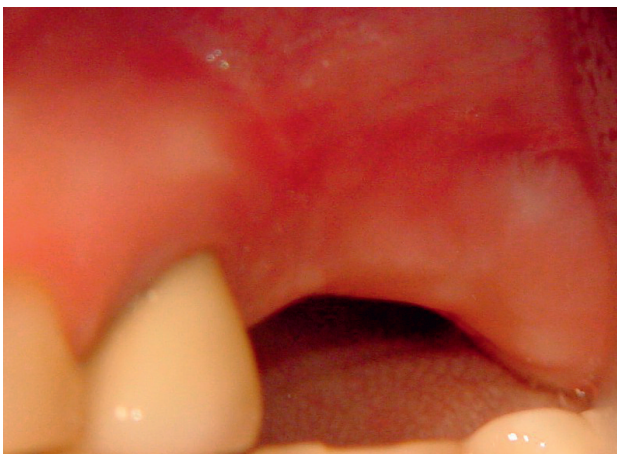*Fig. 2:* Occlusal view of the area.



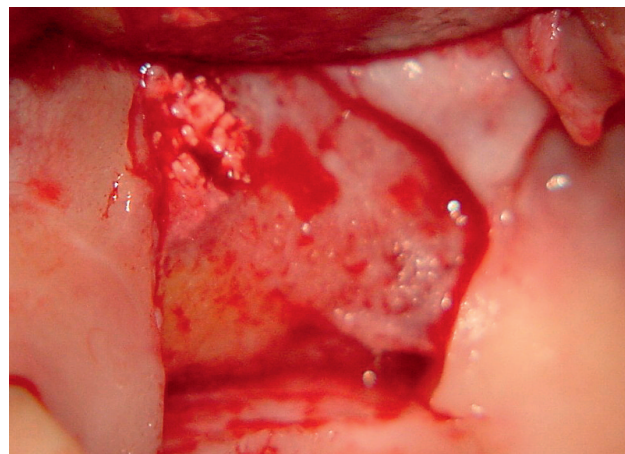
*Fig. 3:* Pre-op X-ray.



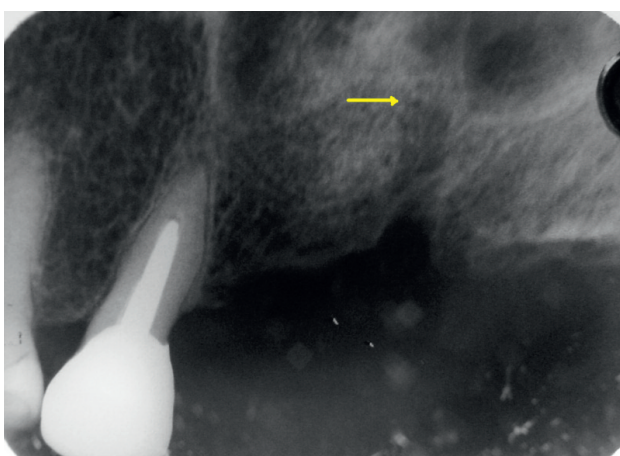
*Fig. 4:* X-ray immediately post-op showing the placement of the  $\beta$ -Tricalcium Phosphate on the maxillary sinus floor -radiolucent area- (day 0).



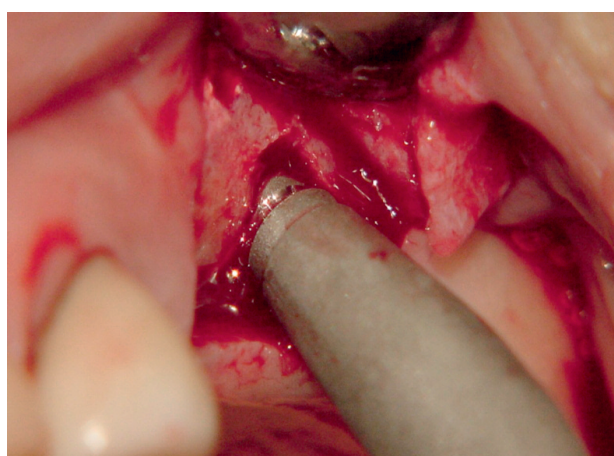
*Fig. 5:* Pre-op clinical image 6 months after  $\beta$ -Tricalcium Phosphate graft "R.T.R." Septodont.



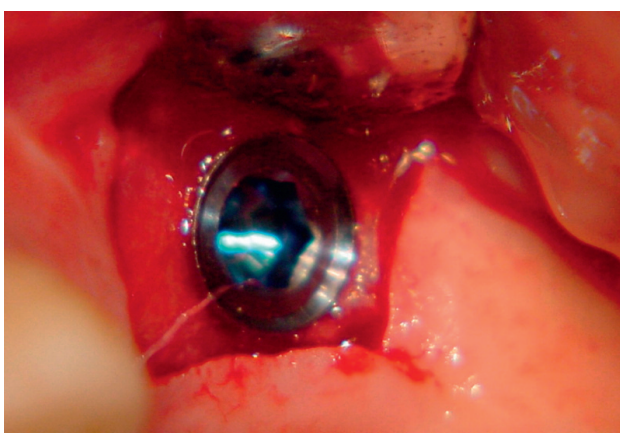
*Fig. 6:* In the window of the sinus lift procedure done 6 months earlier, granules of  $\beta$ -Tricalcium Phosphate "R.T.R." Septodont are observed, which indicates partial replacement with new bone.



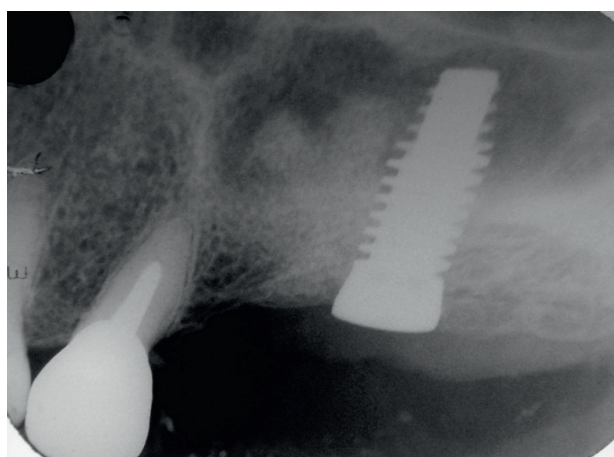
**Fig. 7:** X-ray image to confirm the cutting depth (2.5 mmØ) of the implant receptor site at 10 mm (arrow). Partial replacement of the bone substitute material with receptor bone is obvious.



**Fig. 8:** With osteotomes (Summers technique, 1994) the maxillary sinus floor is lifted 2 mm to achieve insertion of a 12-mm long implant.



**Fig. 9:** Implant 12 mm long by 5 mm diameter placed at bone crest level.



**Fig. 10:** X-ray image showing the placement of the implant.

## Conclusions

Resorption of the alveolar process and pneumatization of the sinus in the edentulous posterior maxilla often represents a clinical challenge in restorative/prosthetic treatment with dental implants (1). Various surgical procedures and graft materials have been used to correct such changes (20-22), including  $\beta$ -Tricalcium Phosphate (23). Miyamoto et al. report "... particles of tricalcium phosphate attract osteoprogenitor cells that migrate into the interconnected micropores of the bone substitute material by six months" (25). The stability of the implants placed at the sites has been evaluated (24). A recent systematic review concludes: "There is a high level of evidence that survival rates of dental implants placed into augmented areas are

comparable with survival rates of implants placed in pristine bone. For maxillary sinus floor elevation, all investigated bone substitute materials performed equally well compared with bone, with high dental implant survival rates and adequate histomorphometric data" (3). The two cases presented show satisfactory results in the use of the bone graft material,  $\beta$ -Tricalcium phosphate "R.T.R." Septodont based on the evidence reported. This, along with the availability of the material and its safety in use, make it a therapeutic choice with multiple benefits.





**Author: Dr Mario Ernesto García-Briseño**

DDS at Universidad Autónoma de Guadalajara, México, 1976.

Certificate program in Periodontology at Universidad Nacional Autónoma de México 1985-87.

Director and Professor of the certificate program in Periodontology since 1992 to date at Universidad Autónoma de Guadalajara School of Dentistry.

Professor of Periodontology at certificate programs in Endodontics,

Orthodontics, and Oral Rehabilitation since 1992 at Universidad Autónoma de Guadalajara School of Dentistry.

Founder and President of the Mexican Association of Periodontology 1996-98.

Founding member and Secretary of the Mexican Board of Periodontology 1996/2001.

Academy affairs coordinator College of Dental Surgeons of Jalisco 2000/2004.

Founder and academic coordinator of the College of Periodontics GDL.

National and international lecturer.

Private practice in Periodontics and Implant Dentistry.

## References

- 01 Schulze-Späte, U., Dietrich, T., Kayal, R. A., Hasturk, H., Dobeck, J., Skobe, Z. & Dibart, S. (2012) Analysis of bone formation after sinus augmentation using  $\beta$ -tricalcium phosphate. *Compendium of Continuing Education in Dentistry* 33, 364–368.
- 02 Al-Nawas B, Schiegnitz E: Augmentation procedures using bone substitute materials or autogenous bone – a systematic review and meta-analysis. *Eur J Oral Implantol* 2014;7(Suppl2):S219–S234.
- 03 Klein MO, Al-Nawas B. For which clinical indications in dental implantology is the use of bone substitute materials scientifically substantiated? *Eur J Oral Implantol* 2011;4:11–29.
- 04 LeGeros RZ. Properties of osteoconductive biomaterials: calcium phosphates. *Clin Orthop Relat Res* 2002;(395):81–98.
- 05 Daculsi G, LeGeros RZ, Heughebaert M, Barbieux I. Formation of carbonate apatite crystals after implantation of calcium phosphate ceramics. *Calcif Tissue Int* 1990; 46: 20-7
- 06 Cutright DE, Bhaskar SM, Brady JM, Getter L, Posey WR. Reaction of bone to tricalcium phosphate ceramic pellets. *Oral Surg Oral Med Oral Pathol* 1972; 33 : 850-6.
- 07 Ghosh SK, Nandi SK, Kundu B, Datta S, De DK, Roy SK, et al. In vivo response of porous hydroxyapatite and  $\beta$ -tricalcium phosphate prepared by aqueous solution combustion method and comparison with bioglass scaffolds. *J Biomed Mater Res B Appl Biomater* 2008; 86 : 217-27.
- 08 Hing KA, Wilson LF, Buckland T. Comparative performance of three ceramic bone graft substitutes. *Spine J* 2007; 7 :475-90.
- 09 Cameron HU, Macnab I, Pilliar RM. Evaluation of biodegradable ceramic. *J Biomed Mater Res* 1977; 11 : 179-86.
- 10 Zhang M, Wang K, Shi Z, Yang H, Dang X, Wang W. Osteogenesis of the construct combined BMSCs with  $\beta$ -TCP in rat. *J Plast Reconstr Aesthet Surg* 2008; 10:1016
- 11 Hak DJ. The use of osteoconductive bone graft substitutes in orthopaedic trauma. *J Am Acad Orthop Surg* 2007; 15 : 525-36.
- 12 Labanca M., Leonida A., Rodella FL: Natural synthetic biomaterial in Dentistry: Science and ethics as criteria for their use. *Implantologia* 2008; 1:9-23
- 13 Smiler DG, Johnson PW, Lozada JL, et al. Sinus lift grafts and endosseous implants. Treatment of the atrophic posterior maxilla. *Dent Clin North Am* 1992;36:151-186.
- 14 Metsger D.S. et al. (1982). Tricalcium phosphate ceramic--a resorbable bone implant: review and current status. *J Am Dent Assoc.*105: 1035-1038.
- 15 Boyne PJ, James RA. Grafting of the maxillary sinus floor with autogenous marrow and bone. *J Oral Surg.* 1980;38(8):513-616.
- 16 Tatum H Jr. Maxillary and sinus implant reconstructions. *Dent Clin North Am.* 1986;30(2): 207-229.
- 17 Summers RB. A new concept in maxillary implant surgery: the osteotome technique. *Compend Contin Educ Dent.* 1994;15(2):152-162.

## References

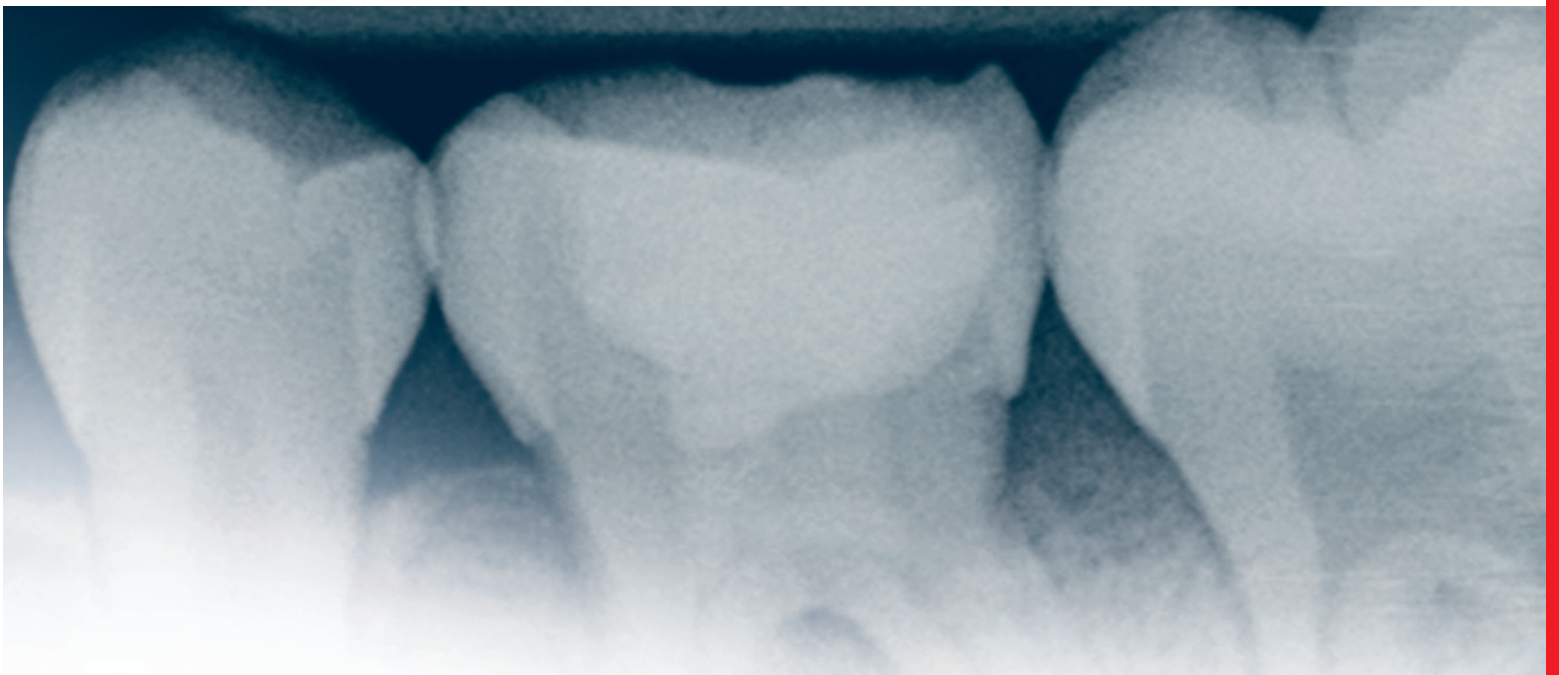
- 18 Davarpanah M, Martinez H, Tecucianu JF, et al. The modified osteotome technique. *Int J Periodontics Restorative Dent*. 2001;21(6):599-607
- 19 Velich N, Nemeth Z, Toth C, Szabo G. Long-term results with different bone substitutes used for sinus floor elevation. *J Craniofac Surg* 2004;15:38-
- 20 Browaeys H, Bouvry P, De Bruyn H. A literature review on biomaterials in sinus augmentation procedures. *Clin Implant Dent Relat Res* 2007;9:166-177
- 21 Nkenke, E., Schlegel, A., Schultze-Mosgau, S., Neukam, F. W. & Wiltfang, J. (2002) The endoscopically controlled osteotome sinus floor elevation: a preliminary prospective study. *International Journal of Oral and Maxillofacial Implants* 17, 557-566.
- 22 Uckan, S., Deniz, K., Dayangac, E., Araz, K. & Ozdemir, B. H. (2010) Early implant survival in posterior maxilla with or without beta-tricalcium phosphate sinus floor graft. *Journal of Oral and Maxillofacial Surgery* 68, 1642-1645.
- 23 Zerbo, I. R., Zijdeveld, S. A., de Boer, A., Bronckers, A. L., de Lange, G., ten Bruggenkate, C. M. & Burger, E. H. (2004) Histomorphometry of human sinus floor augmentation using a porous beta-tricalcium phosphate: a prospective study. *Clinical Oral Implants Research* 15, 724-732.
- 24 Rombelli L, Franceschetti G, Stacchi C, Minenna L, Riccardi O, Di Raimondo R, Rizzi A, Farina R. Minimally invasive transcrestal sinus floor elevation with deproteinized bovine bone or  $\beta$ -tricalcium phosphate: a multicenter, double-blind, randomized, controlled clinical trial. *J Clin Periodontol* 2014; 41: 311-319
- 25 Miyamoto S, Shinmyozu K, Miyamoto I, Takeshita K, Terada T, Takahashi T. Histomorphometric and immunohistochemical analysis of human maxillary sinus floor augmentation using porous  $\beta$ -tricalcium phosphate for dental implant treatment. *Clin. Oral Impl. Res.* 24 (Suppl. A100), 2013, 134-138.

# Download the complete series

## Septodont Case Studies Collection

[www.septodont.com](http://www.septodont.com)





# Biodentine™

## Pulpotomy on a 6-year molar

Prof. Dr Luc Martens  
Dr Rita Cauwels  
Department of Pedodontics - UZGent

Several articles on Biodentine™ were published last year concerning its properties, handling and clinical applications. In this new article, we wish to present a special indication, that of pulpotomy on a permanent six-year molar.

### Introduction

Carious foci on six-year molars can sometimes be surprisingly deep and can extend to the pulp in young patients. Also, developmental difficulties, after which six-year molars are less well mineralized and hence more susceptible to caries, can occur. A well-known example of this is the cheese molar. Therefore, an indication for complete endodontic treatment can arise in the case of both normally formed teeth and these more fragile teeth. Performing such treatment adequately on an immature six-year molar is no easy task. On the one hand there is the child himself and on the other hand there is the immature molar, the roots of which are not yet fully grown. Previously, we have suggested pulp capping with Biodentine™ for minor pulpal lesions which resulted in continued root formation.

In cases of very deep caries or hypomineralization and consequent fragile dentin with severe

hypersensitivity and also taking into account the remaining teeth, we may opt for temporary preservation of that tooth. Complete pulpotomy can then be performed. This choice can be made with a view to subsequent treatment by extraction. The objective then is that the second molars - which erupt on average at around 12 years - take over spontaneously from the six year molars after extraction. The pulpotomy presented here can be regarded as permanent or as a temporary treatment until the most appropriate time for extraction. In the meantime, the child remains problem-free.

### Time of extraction

It is advisable to wait until calcification of the bifurcation or trifurcation, respectively, begins.



This can be seen best in the lower jaw and appears on the radiographic image as a white half moon. At this time, the second molar will move mesially without rotation of the germ (thereby creating a “lying down” molar). A mesial tilt can still be avoided to a certain extent. Orthodontic correction is sometimes necessary. The most important result is for the young child to rid themselves of their malformed or very severely carious molars and recover a healthy set of teeth.

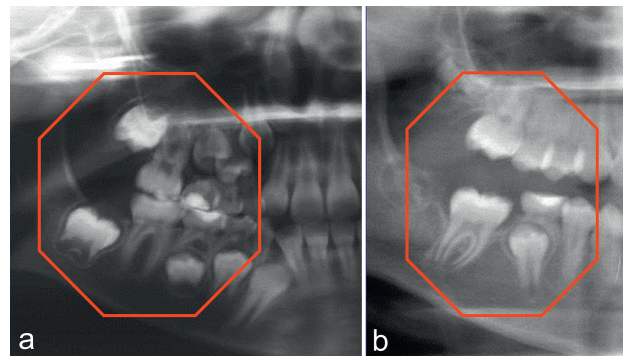
### Orthodontic considerations

When removing the first molar in any quadrant, it is possible to assess whether it is appropriate also to perform a symmetrical (balancing) extraction or an extraction from the opposing quadrant (compensating). As regards the latter, when a tooth is extracted from the lower jaw, extraction should also be performed from the upper jaw, otherwise spontaneous egression of the upper molar will obstruct the mesialization of the lower second molars. From an orthodontic point of view, there is no evidence to support symmetrical extraction. We would emphasize here that we are talking about a normal Class I occlusion. In all cases of Class II and Class III occlusion, the orthodontist should be consulted first.

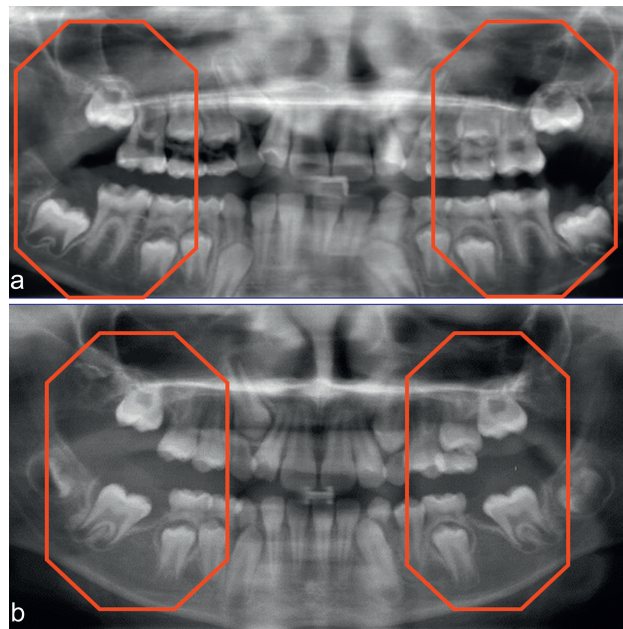
Figures 1a and 1b illustrate the way in which the second molars mesialize perfectly towards the position of the first molars after extraction of 16 and 46. Figures 2a and 2b illustrate the migration of the second molars in all quadrants after extraction of the first molars. This appears to be perfectly successful in the upper jaw; in the lower jaw, there may be a mesial tilt which it would be preferable to correct. In any case, the continued formation of the second molars is clearly seen.

### Pulpotomy with Biodentine™

Complete pulpotomy of the six-year molar is fully comparable with pulpotomy of primary molars. The pulp-chamber roof is removed



*Fig. 1:* Illustration of two cheese molars 16 and 46 (a) and spontaneous mesialization of 17 and 47 after extraction of the first molars. Note the start of calcification of the bifurcation at the time of extraction (a)



*Fig. 2:* Illustration of the extraction in all quadrants of the six-year molars and mesialization of all second molars (b). Note the start of calcification of the bifurcation at the time of extraction (a)

completely and the coronal pulp is amputated from the radicular pulp. After hemostasis of the pulpal surfaces at the canal entrances, Biodentine™ is applied and compressed in the direction of the pulp canals. Care should be taken to ensure that the entire bi-trifurcation is sufficiently covered. There is the option of a thin layer of 2-3 mm or a thicker layer to replace all of the dentin. You can opt for direct composite restoration or use Biodentine™ as a temporary filler for a few weeks/months. In case of major coronal loss (cuspid destruction), a steel crown may be applied.

## Case no.1

A 9-year-old girl presented for consultation complaining of spontaneous pain in tooth 36. Deep caries was found. After discussion with the orthodontist, every effort was made to preserve the tooth. Pulpotomy with Biodentine™ was performed. Figure 3 shows the deep caries (a) and the pulpotomy performed, for which a thin 2-3 mm layer of Biodentine™ was tamped onto the bifurcation in the direction of the canal entrances. In this case, we opted for placement of glass ionomer cement as a temporary restoration. With thanks to Sarah de Smedt, dental surgeon and student pedodontist.

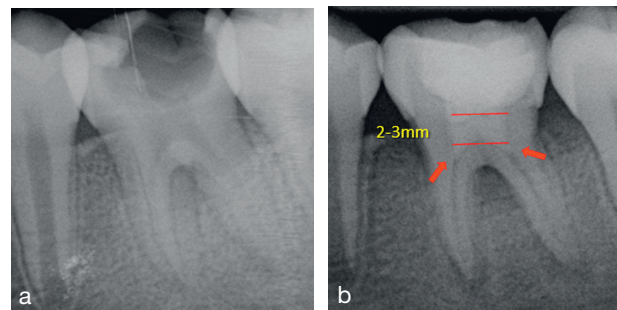


Fig. 3: Illustration of treatment of deep caries at 36 (a) and pulpotomy performed with Biodentine™

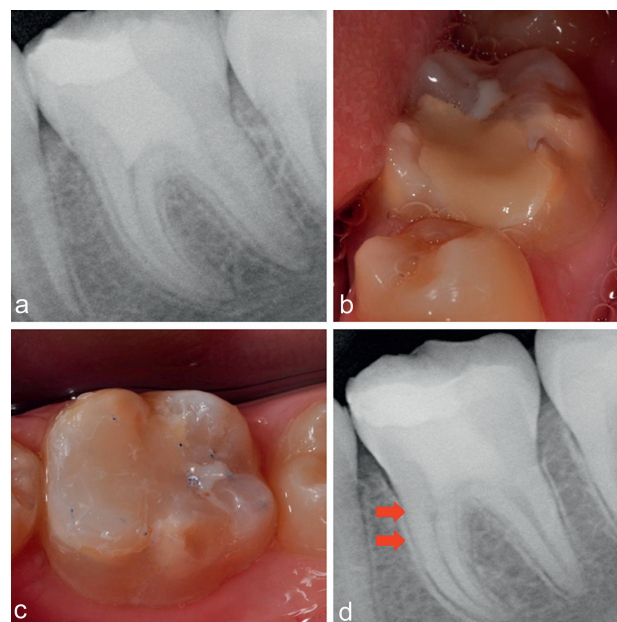


Fig. 4a-d: Illustration of treatment of deep caries at 36 (a) and pulpotomy performed with Biodentine™

## Case no.2

An 11-year-old girl presented complaining of pain. In this case there was sensitivity in tooth 36, diagnosed as a cheese molar. After excavation of deep caries and initial treatment (capping) with Biodentine™, complete pulpotomy was performed at a second visit as the patient continued to complain of pain. Figure 4a shows how Biodentine™ was applied to the pulp chamber and tamped towards the canal entrances. Biodentine™ remained in place as a temporary filling for 6 months (Fig. 4b). No clinical problems arose. Biodentine™ was reduced and a composite filling was put in place (Fig. 4c). A control radiograph at 10 months (Fig. 4d) showed signs of calcification in the mesial canals. This had also been illustrated earlier in relation to primary molars.

## Conclusion

Initial experience and 1-year post-treatment follow-up do not show any problems after pulpotomy is performed on permanent molars with Biodentine™.

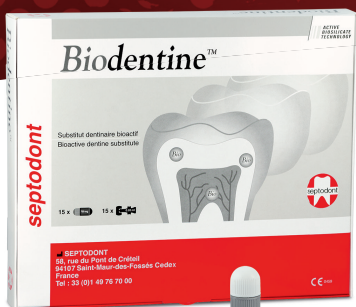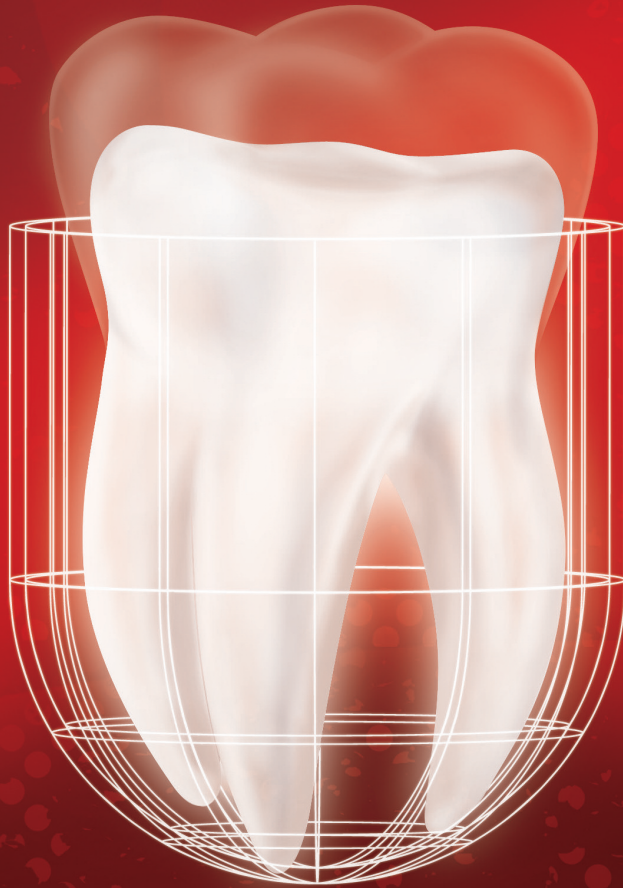
This is in line with recent results in which the same technique was performed with MTA.

## References

- Jälevik B, Möller M. Evaluation of spontaneous spaceclosure and development of permanent dentition after extraction of hypomineralized permanent first molars. *Int J Paediatr Dent* 2007; 17: 328-335.
- Lygidakis NA. Treatment modalities in children with teeth affected by molar-incisor enamel hypomineralisation (MIH): a systematic review. *Eur Arch Paediatr Dent* 2010; 11(2): 65-74.
- Lygidakis NA, Wong F, Jälevik B, Vierrou AM, Alaluusua S, Espelid I. Best clinical practice guidance for clinicians dealing with children presenting with molar incisor hypomineralisation (MIH). *Eur Arch Paediatr Dent* 2010; 11(2): 75-81.
- Nosrat A, Seifi A, Asgary S. Pulpotomy in caries-exposed immature permanent molars using calcium-enriched mixture cement or mineral trioxide: a randomized clinical trial. *Int J Paed Dent*:2013;23:56-63.

# Biodentine™

The first and only dentin in a capsule



ACTIVE  
BIOSILICATE  
TECHNOLOGY

As the **first all-in-one** biocompatible and bioactive **dentin substitute**, Biodentine™ fully replaces dentin wherever it's damaged.

Biodentine™ helps the remineralization of dentin, preserves the pulp vitality and promotes pulp healing. It replaces dentin with similar biological and mechanical properties.

Improving on **Biodentine™** clinical implementation, you can now bond the composite onto Biodentine™ in the same visit and perform the **full restoration in a single session**.

To enjoy the clinical benefits of the first and only dentin in a capsule, ask your dental distributor for Biodentine™.





# Biodentine™

## Apexogenesis

Dr Rita Cauwels

Prof. Dr Luc Martens

Department of Pedodontics - UZGent

Immature teeth, thanks to the open apex, are well vascularized and have an interesting tissue structure at the apical level at the stage of development that allows regeneration as a reaction to tissue damage. Tissue damage can occur following deep caries or as a result of traumatic injury. When pulp necrosis occurs, it is possible in the best case scenario to perform apexogenesis which, when successful, results in a normal root length and well-developed root dentin. In less favorable circumstances, apexification is achieved in which only an apical barrier is observed and a short root with thin, fragile dentin walls is preserved (Chueh & Huang, 2006).

## Introduction

Two types of cells are necessary for normal root development, odontoblasts and epithelial cells of Hertwig epithelial root sheath. Both are present in abundance in the apical zone of immature teeth and are incredibly resistant to destruction, even in the presence of inflammation (Huang et col., 2008; Youssef, 1988). To preserve these cells, it is essential to treat as conservatively as possible if apexogenesis is to be encouraged. It can be assumed that everything depends largely on the duration of the infection, the microorganisms present, the patient's natural resistance and the size of the open apex (Chueh & Huang, 2006).

Quite often, when pulp necrosis is found in an immature tooth, part of the vital pulp remains. Part of this residual vital pulp tissue can be removed so that the root can continue to mature with the aid of the apexogenesis procedure. The guidelines on this subject are not yet fully established but the literature is largely unanimous in this regard (Bose et col., 2009; Chueh & Huang, 2006; Jung & col., 2008; Iwaya et col., 2008; Banchs & Trope, 2004; Huang et col., 2008).

In order to work as conservatively as possible, the use of endodontic instruments is avoided. Instrumentation is replaced by copious irrigation



with 2.5% NaOCl to remove the necrotic tissue, followed by a final rinse with physiological saline. Some authors recommend applying a temporary antibacterial dressing such as calcium hydroxide (CH) paste for a few days first (Iwaya & col., 2008; Bose et col., 2009). Others avoid using CH as a temporary dressing so as not to damage the residual vital tissues with the characteristic high pH of CH (Banchs & Trope, 2004). Opinions on this subject are therefore still divided. In Ghent, we opt mostly for a short treatment (1 week) with CH. When a temporary dressing has been applied, the canal is rinsed in the same way at the second visit and dried with inactive paper points. In the case of a wide open canal, red vital tissue can sometimes be clearly seen deep inside. Touching

it with a paper point can feel sore to the patient, even after administering local anesthesia. This clearly indicates the presence of vital tissue. When the vital pulpal residues are situated at a deeper level, elastic resistance will be clearly felt when inserting a paper point or gutta-percha cone (Jung et col., 2008). As soon as the residual pulp is located in a dry canal, a tricalcium silicate cement such as Biodentine™ is placed in direct contact with the vital pulp tissue. If desired, Biodentine™ can also be placed in the crown as a temporary restoration.

The following case report illustrates the placing of Biodentine™ in contact with the residual vital pulp with the aim of achieving apexogenesis.

## Case report

A 10-year-old girl presented following a dental trauma with subluxation of lateral and central incisors 12 and 11. Owing to their increased mobility, both teeth were repositioned and stabilized with a flexible splint for 3 weeks (Fig. 1a, b). During follow-up, radiographic and clinical tests were performed to diagnose possible pulp necrosis. Both teeth reacted negatively to cold stimuli but showed no other signs of necrosis. Both teeth still had an open apex. However, three months after the trauma we noted complete necrosis of 11 and the patient felt no pain. It was decided to perform complete canal obturation. Six months after the trauma, we also detected incipient necrosis of 12; the tooth still reacted negatively to cold stimuli and also had a distinct brownish-gray color on the palatal side.

However, the patient did not report any pain. On endodontic opening and after irrigation, we found necrosis in the coronal third. The vital tissue was clinically visible and was sensitive to the touch, despite the prior administration of local anesthetic. After drying the coronal third

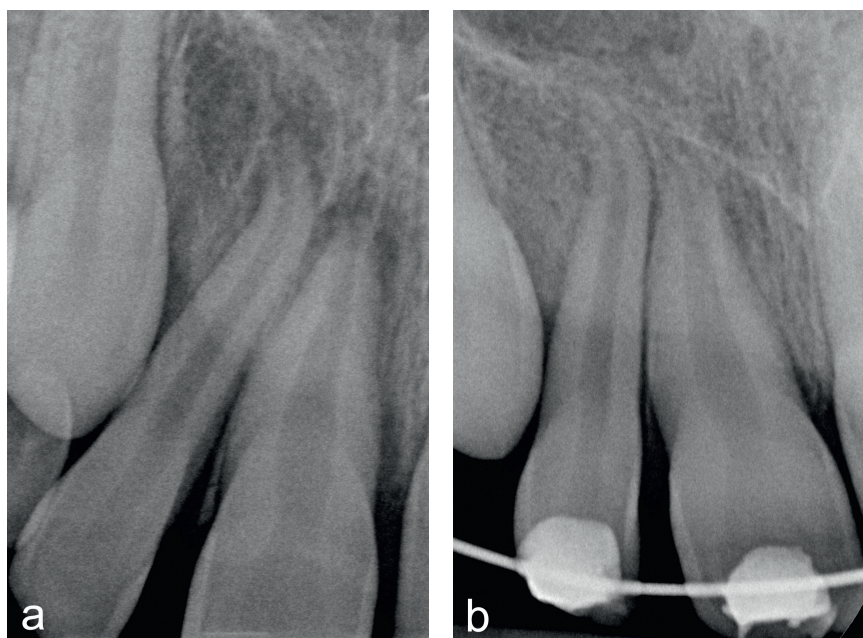
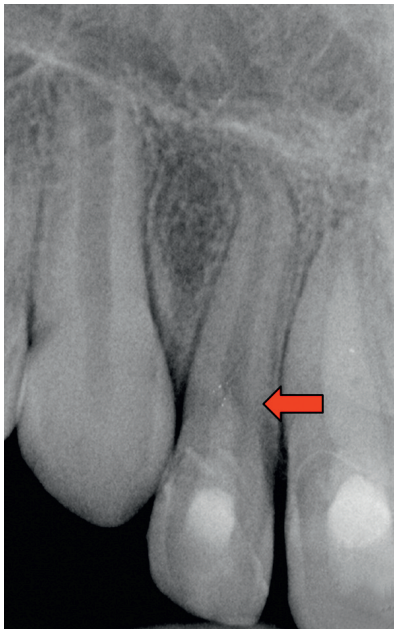


Fig. 1: Radiograph after trauma showing subluxation of 11 and 12 (a) and after repositioning and splinting (b)

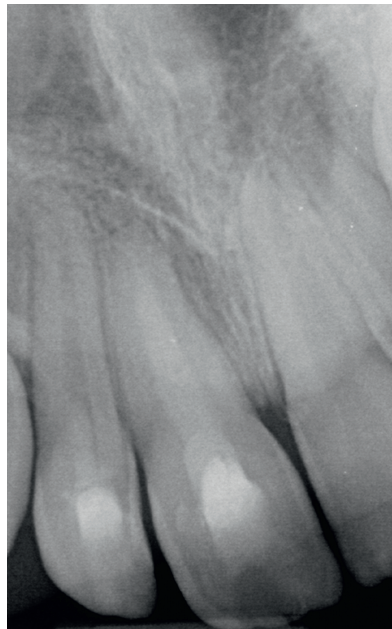

of the canal with an inactive paper point, Biodentine™ was placed, at the same visit, in contact with the residual vital pulp tissue (Fig. 2). Figure 3 shows the control radiograph of the partial endodontic treatment of 12. The tooth now shows slight sensitivity to cold. The patient does not report the slightest pain or discomfort.

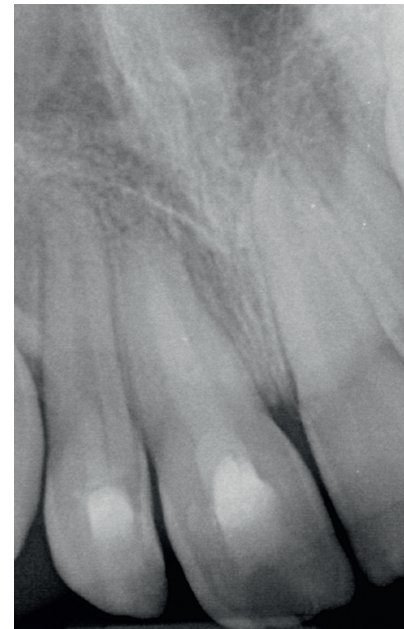During follow-up at 9 months, tooth 12 showed sensitivity to cold more clearly. There was also radiographic evidence of continued maturation (Fig. 4). Clinically, there have been no complaints to date and, from an esthetic point of view, no discoloration of the treated teeth has been observed (Fig. 5 a, b).



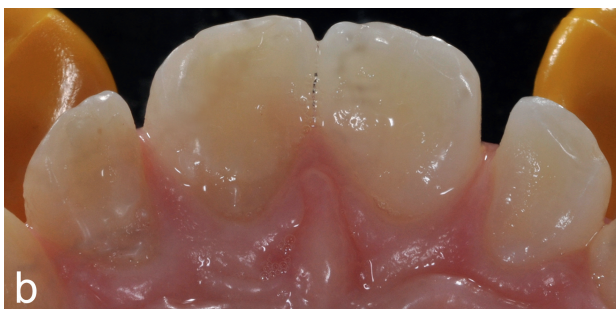
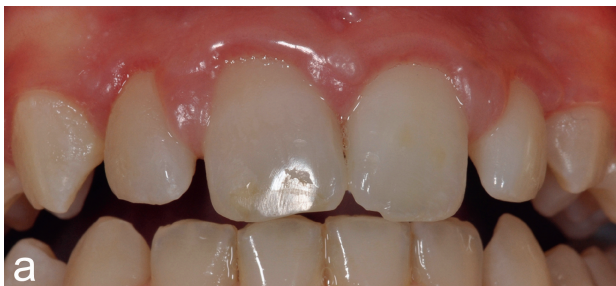**Fig. 2:** RX of 12 after Biodentine placement in the root canal coronal third (arrow), 6 months after the trauma. The open apex clearly shows.



**Fig. 3:** Radiograph of 12 after 3 months of follow-up. Continued maturation is visible. 12 now reacts slightly to cold testing



**Fig. 4:** Radiograph of 12 after 9 months of follow-up showing continued apexogenesis. Cold testing on 12 remains positive



**Fig. 5 a, b:** Clinical view of 11 and 12 in vestibular (a) and palatal (b) view. No complications were noted despite the presence of Biodentine™ in the coronal area of 12 with Biodentine™ can be observed

## Conclusion

This case was treated conservatively in order to preserve the vital pulp residue as much as possible and to give maximum opportunity for apexogenesis. The treated tooth reached full maturation by increasing the root length and by physiologic closure of the apex. This more recent treatment technique was only made possible by Biodentine™ tricalcium silicate cement.

## References

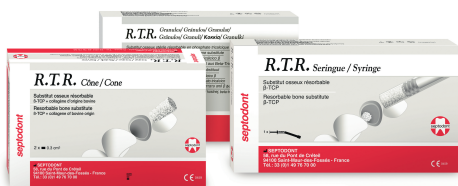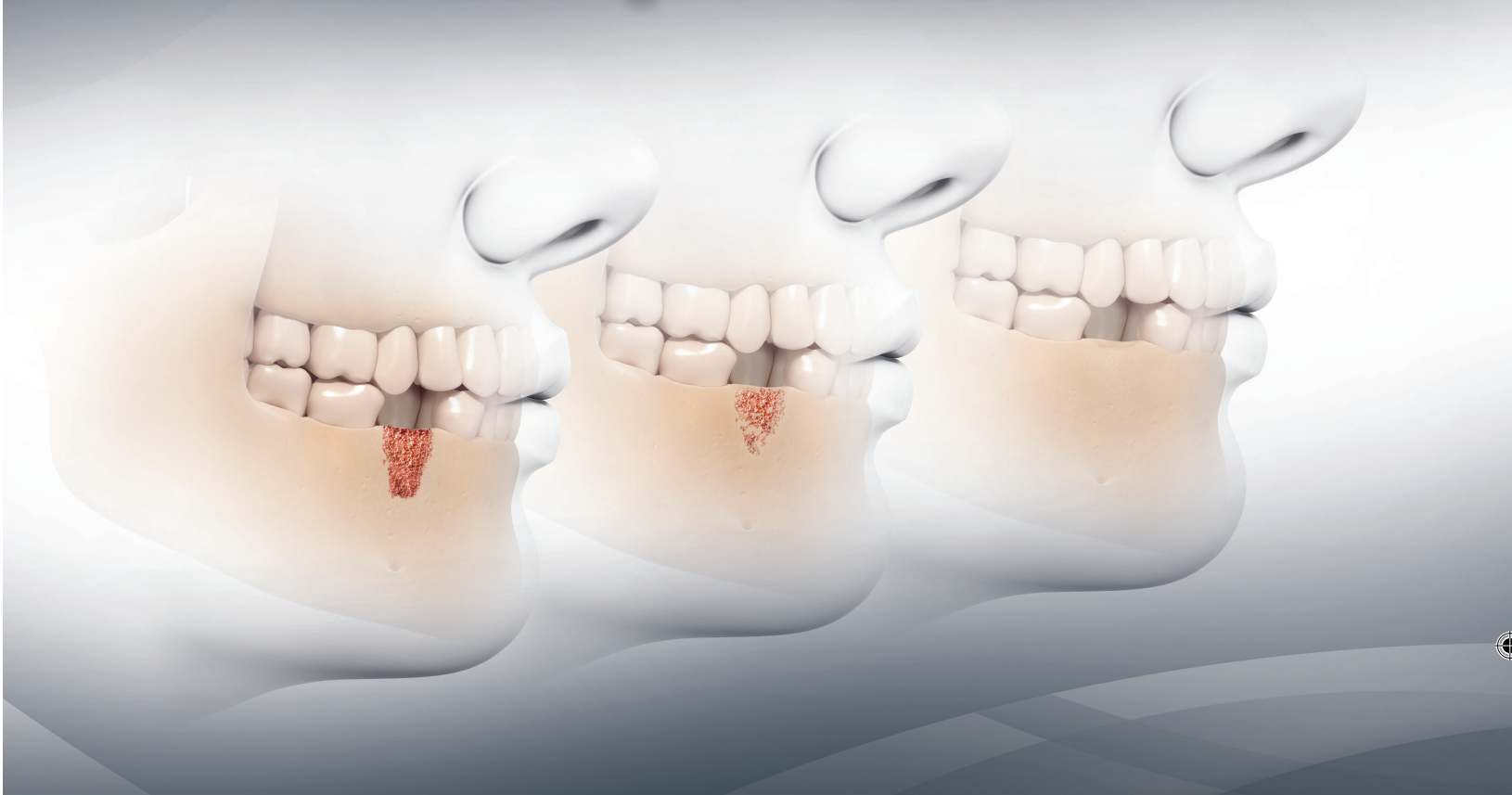---

- 01 Banchs F, Trope M. Revascularization of immature permanent teeth with apical periodontitis: new treatment protocol? *J Endod* 2004;30:196-200.
- 02 Bose R, Nummikoski P, Hargreaves K. A retrospective evaluation of radiographic outcomes in immature teeth with necrotic root canal systems treated with regenerative endodontic procedures. *J Endod* 2009;35:1343-1349.
- 03 Chueh L-H, Huang G T-J. Immature teeth with periradicular periodontitis or abscess undergoing apexogenesis: a paradigm shift. *J Endod* 2006;32:1205-1213.
- 04 Huang G T-J, Sonoyama W, Liu Y, Liu H, Wang S, Shi S. The hidden treasure in apical papilla: the potential role in pulp/dentin regeneration and bioroot engineering. *J Endod* 2008;34:645-651.
- 05 Iwaya SI, Ikawa M, Kubota M. Revascularization of an immature permanent tooth with apical periodontitis and sinus tract. *Dent Traumatol* 2001;17:185-187.
- 06 Jung I-J, Lee S-J, Hargreaves KM. Biologically based treatment of immature permanent teeth with pulpal necrosis: a case series. *J Endod* 2008;34:876-887.
- 07 Yousef Saad A. Calcium hydroxide and apexogenesis. *Oral Surg Oral Med Oral Pathol* 1988;66:499-501.
- Zanini M, Sautier JM, Berdal A, Simon S. Biodentine™ Induces Immortalized Murine Pulp Cell differentiation into Odontoblast-like cells and Stimulates Biomineralization. *JOE* 2012;38:9-1220-1226

# R.T.R.

Full resorption...

...Strong new bone formation



Cone



Syringe



Granules

R.T.R. (Resorbable Tissue Replacement) is a highly pure  $\beta$ -tricalcium phosphate bone grafting material that helps to safely create new bone formation following an extraction or any bone loss (intraony defect, sinus-lift...).

- **Resorbs progressively and fully:** R.T.R. releases calcium and phosphate ions helping to promote strong new bone formation.
- **Regenerates natural bone growth.** Osteoconductive micro and macroporous structures foster dense new bone growth.
- **Restores volume:** R.T.R. renews the bone integrity within 3-6 months.
- **Available in 3 presentations** (Cone, Syringe, Granules) to suit all clinical situations.

Improve your patients' extraction therapy and bone loss repair to promote future implant success with R.T.R.

R.T.R. Cone contains collagen from bovine origin





The Dental Pharmaceutical Company

INNOVATIVE, SAFE AND EFFECTIVE SOLUTIONS FOR DENTISTRY WORLDWIDE

