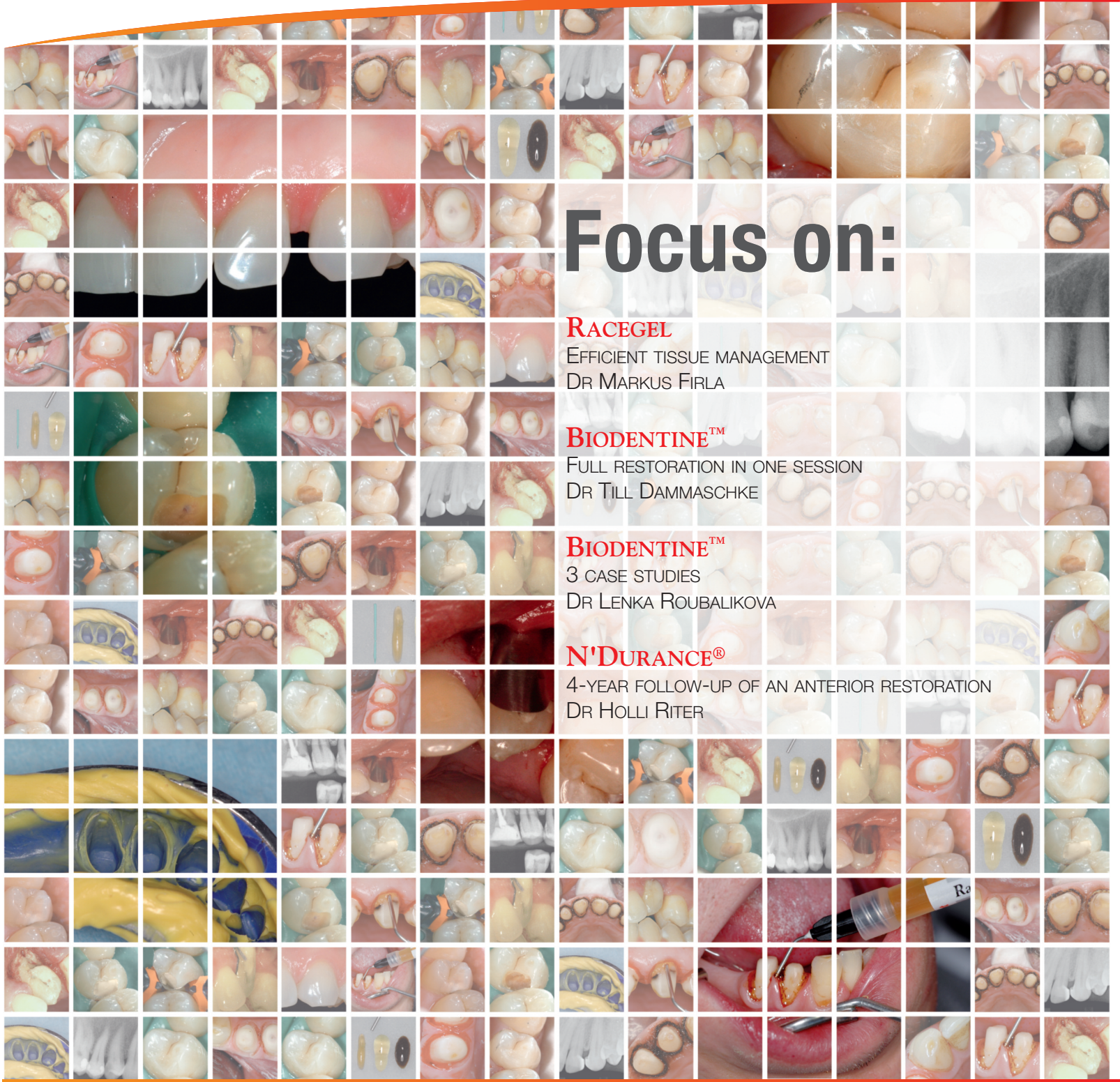

Septodont Case Studies Collection

No. 02 - June 2012



Focus on:

RACEGEL
 EFFICIENT TISSUE MANAGEMENT
 DR MARKUS FIRLA

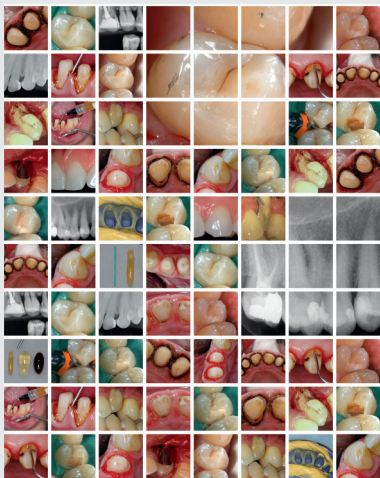
BIODENTINE™
 FULL RESTORATION IN ONE SESSION
 DR TILL DAMMASCHKE

BIODENTINE™
 3 CASE STUDIES
 DR LENKA ROUBALIKOVA

N'DURANCE®
 4-YEAR FOLLOW-UP OF AN ANTERIOR RESTORATION
 DR HOLLI RITER



Editorial



Since its foundation Septodont has developed, manufactured and distributed a wide range of high quality products for dental professionals.

Septodont recently launched innovations in the field of gingival preparation, composites and dentine care with the introduction of Racegel, the N'Durance® line and Biodentine™, which are appreciated by clinicians around the globe.

Septodont created the “Septodont Case Studies Collection” to share their experience and the benefits of using these innovations in your daily practice.

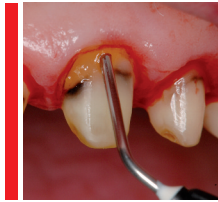
This Collection consists in a series of case reports and will be published on a regular basis.

The second issue is dedicated to three of these innovations:

- **Racegel** a unique reversible thermo-gelifiable gel for gingival preparation. Racegel is easy to put in place, quick to eliminate and atraumatic for the gingival tissues. It also controls bleeding and gingival oozing, creating ideal conditions for impression taking.
- **Biodentine™**, the first biocompatible and bioactive material to be used wherever dentine is damaged. Biodentine™ uniqueness not only lies in its innovative bioactive and “pulp-protective” chemistry, but also in its universal application, both in the crown and in the root.
- **N'Durance®**, the first universal composite based on our exclusive Nano-Dimer Technology. N'Durance® unique combination of low shrinkage and high conversion offers extra biocompatibility and durability to your restorations.



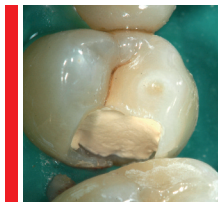Content



Efficient tissue management with Racegel

Dr Markus Th. Firla, DDM

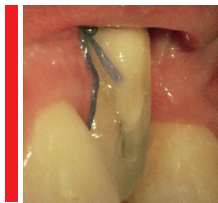
04



Direct pulp capping with Biodentine™

Dr Till Dammaschke, Assistant Professor, DDM
Department of Operative Dentistry

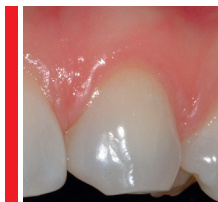10



Personal Clinical Experience with Biodentine™

Docent MU Dr. Lenka Roubalíková, PhD

16



A Four Year Retrospective Case Study in the Use of N'Durance® Composite

Dr Holli Riter, Assistant Professor, DDS

20

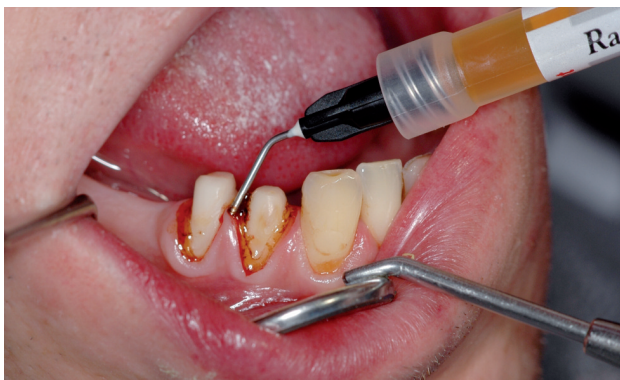

Efficient tissue management with Racegel

The use of a special aluminium chloride gel with reversible temperature-responsive viscosity permits optimised control of bleeding and retraction in the region of the sulcus

reproduced with kind permission of Deutscher Ärzte-Verlag

Dr Markus T. Firla



Since it was not possible to insert cords for the retraction of the marginal gingiva, but at the same time, it was imperative to achieve efficient, but gentle, haemostasis before taking the impression, the measure chosen for the necessary tissue management was the aluminium chloride gel Racegel with ambient temperature-responsive reversible viscosity. This sophisticated material-science property enables the material to be comfortably applied selectively even to the narrowest region of the sulcus before it gels into a stable form as desired due to the warm temperature of the mouth. Note the uniform gel strand on the right (here, clearly orange in contrast to the pale pink gingiva) in the sulcus region of the prepared teeth.

Materials for the efficient, that is - from a practitioner's viewpoint - quick and gentle achievement of dry and clearly visible marginal gingival conditions are of great benefit in daily tooth care routine involving direct or indirect treatment. However, the measures used for a procedure of this kind, known as tissue management, not infrequently take as much time as the subsequent tooth filling or the preceding preparation of the natural crown of the tooth. Therefore, this article describes an innovative product which is extraordinarily suitable for satisfying the clinical requirements for the efficient performance of tissue management.

The “three components” of tissue management

The accurate depiction of dental structures for restorative or prosthetic measures is an absolute requirement when paramarginal, submarginal or inframarginal tooth surfaces have to be worked on or reliably identified for further treatment stages. This procedure, which is as a whole termed tissue management, consists - strictly speaking - of three different

partial steps, which, depending upon the requirements of each specific case, are performed individually or in combination:

- **Haemostasis**
- **Contraction** of the marginal gingiva in question (by means of astringent agents),
- **Retraction** of the gingival cuff (by means of mechanical force)



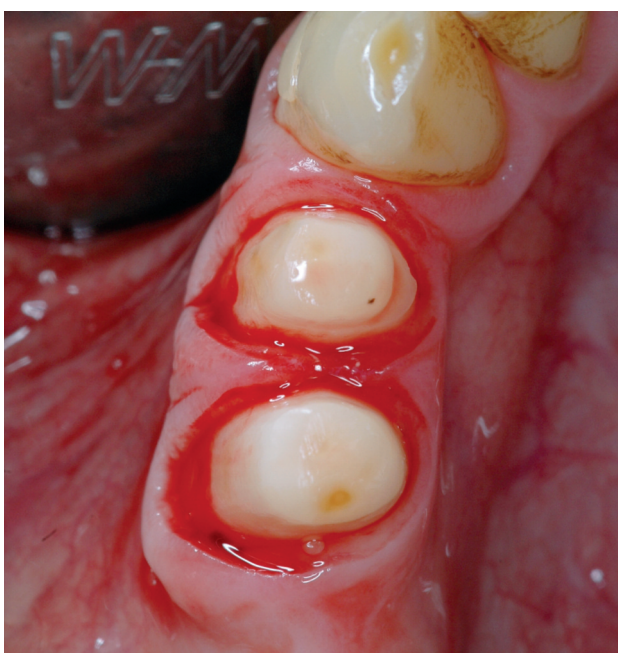Four different products for gingival "tissue management" (haemostasis - contraction - retraction). Reversible temperature-responsive viscous **Racegel** from Septodont (second substance from the left) demonstrates its ability to undergo transient gelling on the glass plate heated to about 30 °C. In these temperature conditions, which are comparable to those in the oral cavity, this product is neither too solid nor too liquid. It is also evident that, compared to other materials, there are no problems discharging it from the thin application syringe at room temperature and that continuously uniform application is possible. Material-specific factors are very beneficial to manipulation both when using retraction cords and without them.

If we ignore the fact that the most reliable method of avoiding bleeding of the sulcus tissue caused by treatment-induced irritation is to protect these structures by means of atraumatic procedures per se or to protect them by means of suitably positioned aids (wedges, cords, protective instruments, etc.), the termination of the bleeding of affected marginal gingival regions may be accelerated by means of agents which act appropriately on these regions, such as, for example epinephrine, aluminium sulfate, iron sulfate and aluminium chloride or locally applied compression by means of cotton rolls or caps, cords placed in the intracrevicular space or the like.

From the clinical aspect, this means that traditional tissue management methods frequently use a combination of measures for haemostasis and retraction of the marginal gingiva in the sulcus region. The classical example is the insertion of a cord, which has previously been soaked in a haemostatic agent, in the gingival pocket. However, this combination of two, in principle very different, processes can result in tissue loss in the marginal periodontium. In particular, in the case of very thin and narrow gingival conditions, otherwise favourable impacts of individual

measures may be detrimental in combination. Therefore, whenever planning manipulations in the marginal periodontium, it is advisable to consider which procedure will be the least compromising for the tissue affected. For example, the use of suitable cords in the dental sulcus region is an excellent possibility for achieving a targeted and efficient, but also gentle retraction of the gingiva and even - depending on the prevailing initial situation - for achieving an additional haemostatic action due to the compression of the microvessels. However, here it is necessary to take into account the length of time that compression acts on individual gingival regions in order to exclude the possibility of subsequent necrosis-inducing ischaemia. Although mechanical retraction in combination with astringent agents is very useful for a bloodless treatment area, consideration should be paid in advance to the total amount of time that will be required.

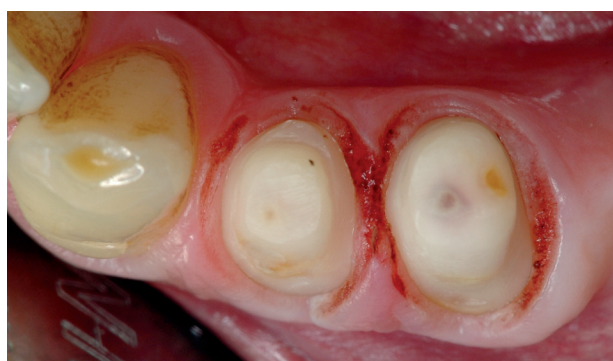For the prudent implementation of tissue management, it is important to know that epinephrine is absorbed via exposed regions of tissue into the organism where it can have detrimental systemic effects, known as the epinephrine syndrome. This can result in tachycardia, raised blood pressure, rapid respiration, headache and anxiety or even psychological stress. In addition, the vasoconstrictive action of epinephrine only lasts for a limited period and, as a result, the vessels in the affected tissue can undergo relaxation during the decisive impression process. Although aluminium sulfate, which has been known as a method for general haemostasis for a long time, does not trigger any adverse systemic effects, but in gingival tissue it can result in an identifiable atrophy of the underlying alveolar crest. Another problem is the unpleasant taste, which not infrequently causes discomfort to the patients treated with this substance. The sulfur content can also inhibit complete setting of addition-curing silicone impression materials if aluminium sulfate is not completely removed from the regions from which an impression is to be taken.



Clinical view directly after the preparation of two mandibular premolars. The grinding of the teeth for the later acceptance of primary telescopic crowns had to be performed without intracrevicular cords protecting the surrounding gingiva since the marginal gingival pockets were only about 0.5 mm deep. However, the instruction to leave the longest possible stumps for stable anchorage of the telescopic crowns did not allow any other option than to allow the preparation limits to extend as far as physiologically acceptable into the sulcus region of the teeth. This resulted in bleeding of the marginal gingiva in the regions affected by the diamond grinding tool.

The latter also applies to iron sulfate, which is one of the most recognised agents for the rapid local arrest of bleeding, since its haemostatic effect is in particular based on intravascular coagulation in the ends of the exposed vessels. However, at the same time, sudden coagulation - including of the blood in the gingival cuff - and the, in some circumstances, resultant extreme accumulation of blackish-brown particles of coagulum in the treated areas can also be seen as a serious drawback specific to this substance since the necessary removal of the superficial blood clots can be time-consuming and laborious.

Like aluminium sulfate, a buffered aluminium chloride solution does not have any systemic effects when applied topically for haemostasis. The tissue damage potential for the gingiva of a 25% aluminium chloride solution is comparable to that of a 15% iron sulfate solution, with both these agents being markedly less harmful to the gingiva than aluminium sulfate.



The prepared premolars from Figures 2 and 3 following two minutes' exposure to the gel containing 25% aluminium chloride and subsequent spraying of the gel with water from the multifunction syringe on the treatment table. Since this special product is rapidly and completely liquefied at low ambient temperatures for tissue management, it can be completely removed rapidly and without problems by means of a water spray. The marginal gingiva have perfect haemostatic conditions and we can also identify a marked contraction of the gingival sulcus tissue. It is also possible clearly to evaluate the status of the stumps and the respective type of preparation.

Racegel

As a buffered glycol-based 25% aluminium chloride gel which exhibits reversible temperature-responsive gelling behaviour, which is very useful to practitioners, **Racegel** is easy to apply without streaking or agglutination. On application to the tooth substance and the marginal gingival tissue, the thermal activation that occurs during adaptation to the temperature conditions in the oral cavity brings about a change in the viscosity of this material allowing its targeted application - since it is initially free-flowing - in a thin strand even to hard-to-access cervical cavities and preparation areas. Then, due to the thermally induced gelling, it remains securely in a dimensionally stable form at the site of the wetting of the periodontium. The excellent adhesive force until sprayed with cooler spray water from the multifunction syringe, even on steep slopes of ground teeth, is a product-specific achievement of material science attributable to the temperature-responsive reversible gelling capacity of this material.

From a clinical aspect, another benefit is that the use of this product does not cause any discoloration of the gingiva. Neither do any

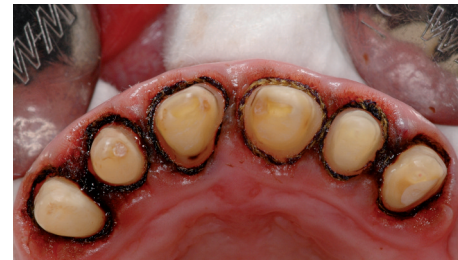blood clots form and so there is no need for laborious cleaning of the visible treatment area. The exposure time required for optimum haemostasis is 2 minutes per application. However, it has been found, that with low bleeding levels, this period can be even shorter due to the very good haemostatic action of this aluminium chloride gel. However, in the case of larger areas of gingival bleeding, it should be noted that, in the case of multiple applications of the material, an overall exposure time of ten minutes for the same area of tissue must not be exceeded in order to avoid the risk of destructive effects on the marginal periodontal tissue.

The pronounced haemostatic effect is accompanied by a clear astringent effect. In suitable cases, this enables mechanical retraction of the free gingiva (for example with cords inserted in the sulcus) to be dispensed with entirely. Particularly with very delicate marginal gingival conditions in aesthetically critical regions

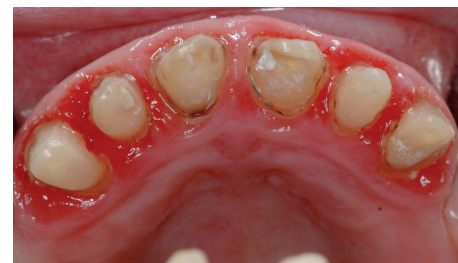of the jaw, it is impossible to overvalue the advantage of this possibility of dispensing with the, in some circumstances - despite the greatest care - excessively traumatic displacement of the marginal gingiva with respect to the retention of the gingival cuff in the treatment area. Particularly with all-ceramic crowns and veneer work in the region of the upper anterior teeth, the risk that the post operationem “by a whisker” aesthetically displeasing atrophied bucco-cervical marginal gingiva of a tooth represents a permanent threat on the incorporation of the finished restoration, even for an experienced, dexterous and cautious practitioner.

Ah. And, the use of **Racegel** avoids yet another problem: the taste which the patients find so unpleasant. On contact with the tongue and its further distribution in the oral cavity, this innovative gel only produces a slightly acid impression with a hint of bitter fruit and with no strong unpleasant aftertaste... The best thing would be to try it for yourself!

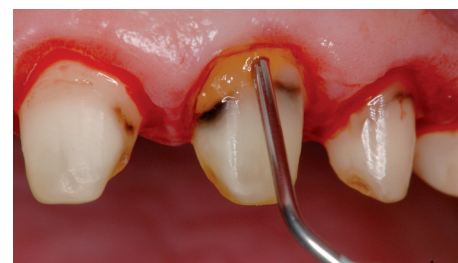
In order to “err on the side of caution”, when taking the impression for the production of the laboratory-made long-term temporaries, before the primary impression during the correctable impression technique after the action and subsequent spraying of the described 25% aluminium chloride gel, knitted cords (Ultrapak Retraction Cords, Ultradent Products) were inserted into the gingival pockets. A perfect, advantageous combination of a chemically-induced haemostatic-contracting action and mechanical retraction. All in all, a gentle yet efficient - and above all rapid - method of tissue management.

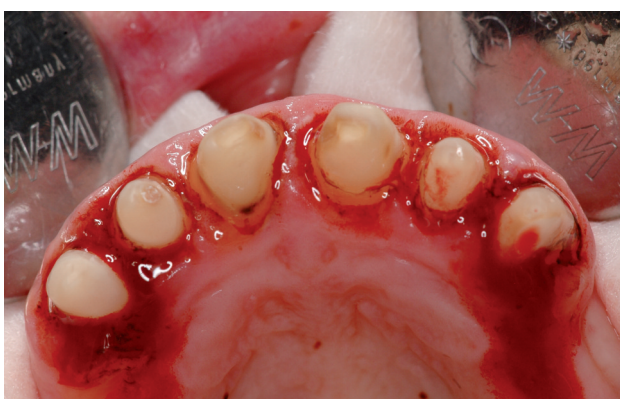

The remaining upper anterior teeth of a 67-year-old female patient following the removal of the splinted single crowns in regions 11 to 13 and 21 to 23. The crowns had to be removed after the presence of combination restorative dentistry for more than 20 years due to the irreversible loss of the removable partial prosthesis during the necessary renewal of the maxillary prosthesis. In the regions of splinted crowns and the locations of the distal attachments on the canine teeth, the marginal gingiva had pronounced inflammation. To enable systematic periodontal treatment to be performed before the final prosthetic care, it is necessary to protect the anterior teeth with “periodontal-friendly” and “oral-hygiene promoting” long-term temporaries. To this end, initial gentle reparation of the teeth is necessary.

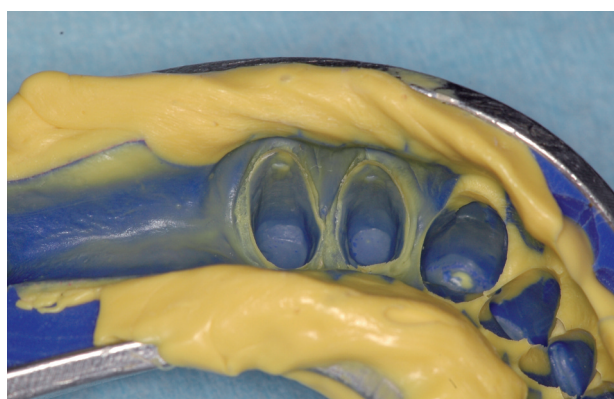


The remaining mild intracrevicular seeping haemorrhage was arrested by another selective application of the gel directly into the marginal sulcus regions. (Note the stable gel layer in the cervical region of the stump of 21 after application from the thin needle). Here, once again, we can see benefits of the thermogelling properties of the material which permit precise application into the desired areas and immediately thereafter effect stable adherence to the wetted solid and soft tissue. The exposure time until repeat spraying was once again two minutes.





Even the most careful preparation caused massive bleeding, which with an initial, relatively extensive application of **Racegel** was virtually completely arrested (see photo). As specified by the manufacturer, Septodont, the aluminium chloride gel was allowed to act for two minutes. After this, the blood and the gel were thoroughly sprayed off using a suitable water spray.



The subsequent correctable impression directly after the impression. Although very delicate due to the extremely shallow sulcus regions, the preparation limits are clearly visible. All quality criteria required to produce a perfect prosthodontic master model have been met. It is also evident that the use of high-dose aluminium chloride gel has not caused any material-induced drawbacks with respect to the curing of the A-silicone used (Hydrorise Putty fast set and Hydrorise Extra Light Body fast set, Zhermack GmbH).

Conclusion

The product **Racegel** for gingival tissue management during precision impressions and fillings extending into the paramarginal or submarginal gingival sulcus, which the manufacturer Septodont launched on the dental market represents an innovative “high-tech material” with which the tissue of the marginal periodontium can be prepared gently with no mechanical injury or pain to the patient. The temperature-responsive variable viscosity of this gel containing 25% aluminium chloride means that, until it has heated up to mouth temperature, it can be applied in free-flowing state by means of extremely fine needles with optimum control, even in hard-to-access gingival pockets. When mouth temperature is achieved and the thermogelling effect sets in, it remains stably in situ without slipping or running off.

The, once again, simple, rapid and complete removal of **Racegel** is greatly assisted by the fact that, when sprayed with water from a multifunction syringe, the temperature of the material drops markedly again returning it to a fluid state in which it can be easily rinsed off. Following the required exposure time of 2 minutes, the atraumatic astringent effect on the periodontal soft tissue is manifested as optimally controlled haemostasis and sulcus opening. Compared to other - not as effective - products, **Racegel** is definitely worth its price, considering the cost-benefit ratio. After all, there is no doubt that the principle “time is money” applies at all stages of efficient gingival tissue management during dental prosthetic measures, including preservative fillings.



Author: Dr Markus T. Firla
Hauptstrasse 55
49205 Hasbergen-Gaste
Email: Dr.Firla@t-online.de

References

1. Firla MT: Productivity counts. Dental Product Report Europe 2007; 28: (2) 43-44.
2. Albers H F: Impressions - A Text for Selection of Materials and Techniques. Ed. I, Alto Books. Santa Rosa 1990.
3. Paffrath C M et al.: Impression - what to consider? ZMK 2008; 24: (10) 654-670.
4. Albers H F: Impression Taking Systems. The Adept Report 1990; 1: (2) 9-16.
5. Wöstmann B et al: Influence of moisture on accuracy of impression in a sulcus-fluid model. Dtsch Zahnärztl Z 1999; 54: (8) 631-633.
6. Wöstmann B: Impression: tips for standardisation. Dtsch Zahnärztl Z 2009; 64: (3) 142-145.
7. Hahn R (ed): Precision Impressions. Practical Guide 5. DentalSchool GmbH. Tübingen 2006.
8. 3M ESPE: Making Better Impressions - Expert Education - Impressioning Trouble Shooting Guide. 3M ESPE AG. Seefeld 2007.
9. Wirz J., Wöstmann B.: Precision Impressions - A Guideline for Theory and Practice. 2nd edition, 3M ESPE AG. Seefeld 1999.



Direct pulp capping with Biodentine™

Full restoration in one session

Dr Till Dammaschke, Assistant Professor, DDM
Department of Operative Dentistry

Summary

Biodentine™ was recently introduced to the dental market as a dentin substitute. This new bioactive calcium silicate cement has a positive effect on vital pulp cells and stimulates tertiary dentin formation. Hence, it can be used for direct pulp capping after pulp exposure. Information originally released by the manufacturer Biodentine™ stipulated to wait for the next appointment before bonding the final composite restoration onto the Biodentine™ base/dentin substitute. Latest research showed that the full restoration can be placed in the same session, therefore improving on Biodentine™ clinical use. This was illustrated in a case report published in Quintessenz Germany end of 2011, showing a 1-year successful clinical follow-up of the restored tooth.

In the present case the pulp of tooth 14 (iatrogenic exposed during caries excavation) of a 43-year-old male patient was directly capped with Biodentine™. The cement was used as a base to replace the dentin layer and a composite restoration was placed to replace the enamel layer. At the follow-up visit after six months the tooth was clinically normal and tested positive

for sensitivity and negative for percussion. The dental film showed the apical region without any pathological findings. Due to its improved material properties, Biodentine™ is an interesting alternative to conventional calcium hydroxide-based materials. It offers advantages for direct pulp capping and, in properly selected cases, may contribute to the long-term maintenance of tooth vitality.

Introduction

In contact with vital pulp tissue calcium hydroxide contributes to the formation of reparative dentin, a special variant of tertiary dentin, which seals exposures with a newly formed hard tissue. This has been documented by basic research and clinical studies with reported success rates in excess of 80 % for direct pulp capping procedures in humans (Baume and Holz 1981, Hørsted et al. 1985, Duda and Dammaschke 2008, Duda and Dammaschke 2009). Calcium hydroxide has been shown to promote the differentiation of odontoblasts or odontoblast-like cells, which will form a hard tissue bridge in the pulp, i.e. calcium hydroxide contributes actively to the

formation of new hard tissue by induction and up-regulation of the differentiation of odontoblast-like cells (Schröder 1972). Furthermore, low concentrated calcium hydroxide induces the proliferation of pulp fibroblasts (Torneck et al. 1983).

However, calcium hydroxide has some major drawbacks that have put into question its continued usage. The compound exhibits poor bonding to dentin, mechanical instability and continued resorption after placement (Barnes and Kidd 1979, Cox et al. 1996, Goracci and Mori 1996). As a result, calcium hydroxide does not prevent microleakage over extended periods even when paired with a sealed restoration. The porosities of the newly formed hard tissue known as tunnel defects may act as portals of entry for pathogenic microorganisms. These can cause secondary inflammation of the pulp tissue and are thought to be responsible for failed maintenance of tooth vitality and dystrophic calcification. In addition, the high pH (12.5) of calcium hydroxide suspensions causes liquefaction necrosis at the surface of the pulp tissue (Barnes and Kidd 1979, Cox et al. 1996, Duda and Dammaschke 2008). Thus, innovative materials have been employed as pulp capping agents and include hydrophilic resins, resin-modified glass ionomer cements, ozone technology, lasers, resins combined with bioactive agents and mineral trioxide aggregate (MTA).

Recently, a new bioactive calcium silicate cement, Biodentine™ (Septodont, St. Maurice-Fossés, France), was launched on the dental market denoted as a dentin substitute. Biodentine™ consists of a powder in a capsule and liquid in a pipette. The powder mainly contains tricalcium and dicalcium silicate, the principal component of Portland cement and MTA, as well as calcium carbonate. Zirconium dioxide serves as contrast medium. The liquid consists of calcium chloride in an aqueous solution with an admixture of modified polycarboxylate. The powder is mixed with the

liquid in a capsule in a triturator for 30 seconds. Once mixed, Biodentine™ sets in about 12 to 15 minutes. During the setting of the cement calcium hydroxide is formed. The consistency of Biodentine™ reminds of that of phosphate cement. Comparable to MTA cements, Biodentine™ can be used for the treatment of root perforations or of the pulp floor, internal and external resorption, apexification, retrograde root canal obturation, direct and indirect pulp capping and pulpotomy, but also for temporary sealing of cavities, and cervical fillings (Laurent et al. 2008, Dammaschke 2011).

Compared to other materials (e.g. Mineral Trioxide Aggregate), Biodentine™ handles easily and needs much less time for setting. Unlike other Portland cement-based products, it is sufficiently stable so that it can be used as well as for pulp protection, base/dentin substitute and temporary fillings at the same time (Pradelle-Plasse et al. 2009). Hitherto, the manufacturer recommended to fill the entire cavity completely with Biodentine™ in a first step and to reduce it to a base/dentin substitute level in a second visit, 48 h to 6 months later, before the definitive restoration. This was recommended because it was not evidenced how dentin adhesives and/or composites adhere on the surface of freshly mixed Biodentine™. Yet, latest research showed that the adhesion of a dentin adhesive on the surface of freshly mixed Biodentine™ was higher than the adhesion of Biodentine™ on dentin (unpublished data). It also showed that the mechanical behavior of the early Biodentine™/Composite restoration is similar to a GIC/Composite restoration (unpublished data).

Therefore, both the mechanical behavior and the adhesion are sufficient to restore a cavity with a composite, directly 12 min to 15 min after Biodentine™ is mixed, in the same appointment. Thus, this case report illustrates the use of Biodentine™ for direct pulp capping in a single-stage approach.

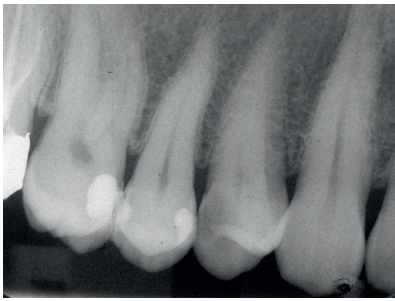

Fig. 1: Radiograph revealed signs of an approximal carious lesion distally on tooth 14.

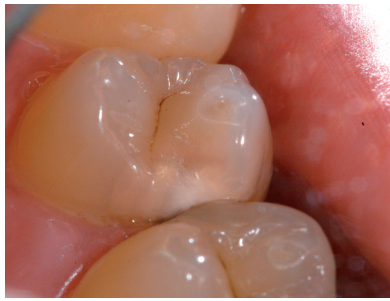

Fig. 2: Diagnostic assessment showed an approximal carious lesion distally on tooth 14.

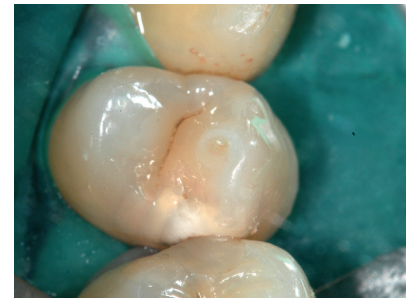

Fig. 3: Rubber dam was put in place.

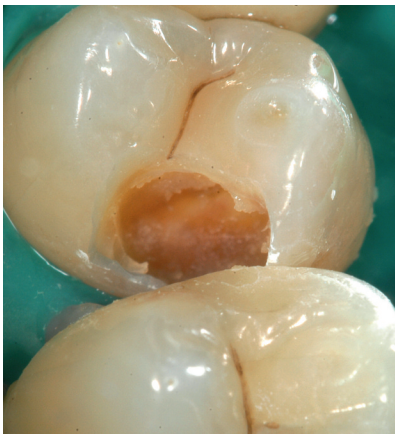

Fig. 4: Cavity preparation and incomplete caries excavation on tooth 14.

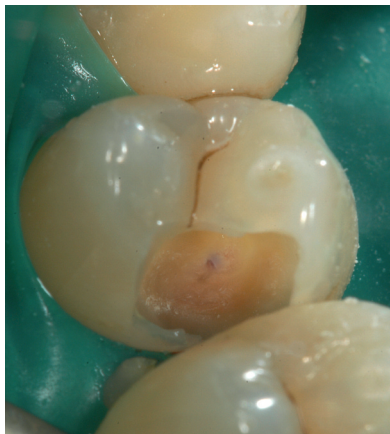

Fig. 5: Iatrogenic pulp exposure occurred during complete caries excavation on tooth 14.

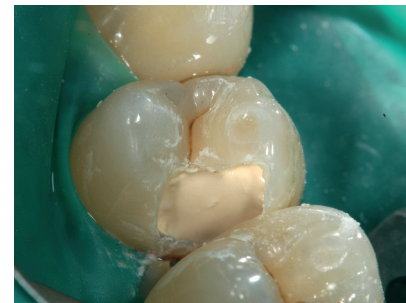

Fig. 6: Biodentine™ (Septodont; St. Maur-des-Fossés, France) was applied to the cavity as a subbase to replace the dentin layer with cement pluggers using light pressure. Biodentine™ should not be prepared with rotating instruments and should not come into contact with water during setting time.

Case report

A 43-year-old male patient came for a routine check-up. Diagnostic assessment as well as a radiograph showed signs of an approximal carious lesion distally on tooth 14 (*Figs. 1 and 2*). The patient was informed about the need of having the carious lesion treated. The tooth was tested positive on CO₂ snow sensitivity and negative on percussion. After thorough information of the patient, an anesthetic (Septanest, 1 ml; Septodont, St. Maur-des-Fossés, France) was injected for terminal anesthesia and a rubber dam was put in place (*Fig. 3*). Following the cavity preparation (*Fig. 4*) the carious dentin was completely excavated. In this process the pulp cavity was exposed iatrogenically (*Fig. 5*). Clinically the pulp tissue was vital without any major bleeding, so that maintenance of tooth vitality by direct pulp capping was decided

upon. Cavity toilet with NaOCl (2.5%) was done for hemostasis, clearing and disinfecting the cavity. Biodentine™ (Septodont, St. Maur-des-Fossés, France) was chosen for direct pulp capping. Mixed as recommended by the manufacturer, Biodentine™ was applied to the exposed pulp tissue for direct capping and as (sub)base to replace the dentin layer (*Fig. 6*). After mixing, Biodentine™ needed 12 min to set before the treatment could be continued. During this time the appearance of the Biodentine™ surface changed from glossy (*Fig. 6*) to matt (*Fig. 7*). Then, a matrix band (Composi-Tight 3D; Garrison, Spring Lake, MI, USA) as well as wedges were applied (*Fig. 8*) and the entire cavity (including the Biodentine™ surface) was treated with a self-etching dentin adhesive (Optibond XTR; Kerr, Orange, CA, USA). Finally, the cavity was restored with a composite filling material (Grandio; VOCO, Cuxhaven, Germany) (*Figs. 9 and 10*).

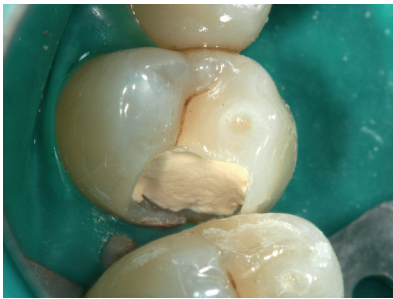

Fig. 7: After the setting of Biodentine™ (12 min minimum) the appearance of the Biodentine™ surface changed from glossy to matt. Now the treatment could be continued.

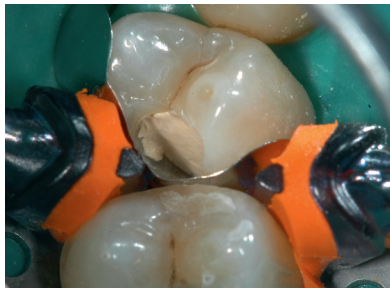

Fig. 8: Before restoring the cavity a matrix band (Composi-Tight 3D; Garrison, Spring Lake, MI, USA) and wedges were put in place.

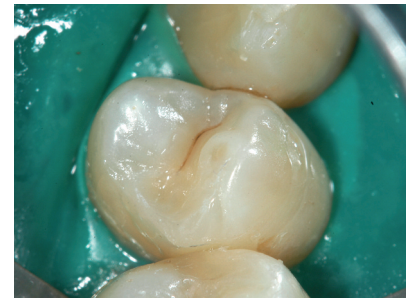

Fig. 9: After allowing 12 to 15 minutes for Biodentine™ to set the cavity filled with composite (Grandio, VOCO, Cuxhaven, Germany).

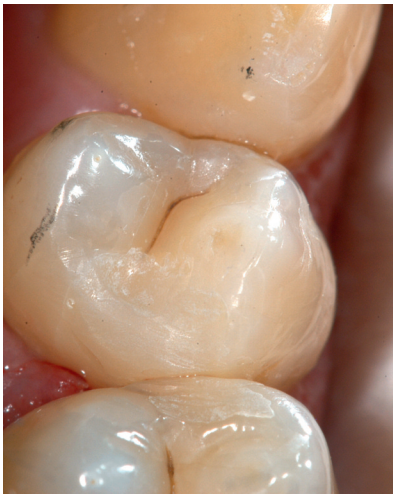

Fig. 10: Finalized and polished composite restoration.

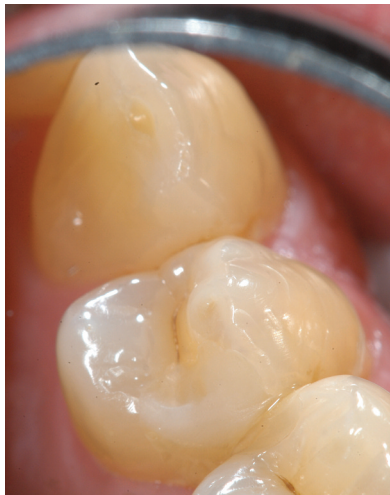

Fig. 11: Composite restoration of tooth 14 six months after restoration.

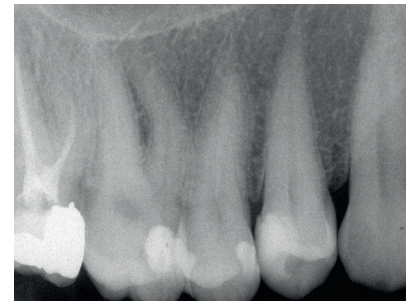

Fig. 12: The dental film recorded six months after direct capping does not show any pathological findings apical of tooth 14. One little deficiency of Biodentine™ can be recognized on this radiograph: the radiopacity of the cement is close to dentin so that the thick layer of Biodentine™ is hardly to differentiate below the well visible composite restoration.

At the follow-up visit 6 months after direct pulp capping tooth 14 was clinically normal (**Fig. 11**) and again tested positive for sensitivity and negative for percussion. The dental film recorded at that time did not show any pathological findings apically (**Fig. 12**). The patient reported about no discomfort on tooth 14 at any time after pulp capping, e.g. upon contact with cold food, drinks and air, or other subjective symptoms.

Discussion

The primary aim of a pulp capping material is to induce a specific hard tissue formation by pulp cells that seal the exposure site and ultimately contribute to continued pulp vitality (Schröder 1985). Clinically, it was shown that Biodentine™

is able to maintain pulp vitality after direct pulp capping (Dammaschke 2011). It is known that calcium silicate cements have the ability to release calcium and hydroxyl ions and to form hydroxyapatite crystals on the surface after contact with phosphate containing liquids like body fluid (Gandolfi et al. 2010, Borges et al. 2011). It can be assumed that Biodentine™ exhibits the same effects as calcium hydroxide, due to the release of calcium and hydroxyl ions, when in contact with water or tissue fluids. Hence, Biodentine™ is biocompatible, i.e. it does not damage pulpal cells in vitro or in vivo, and is capable of stimulating tertiary dentin formation. Histologically, hard tissue formation was seen both after indirect and direct capping with Biodentine™ (Laurent et al. 2008, Laurent et al. 2009, Boukpepsi et al. 2009). Used for pulp capping, the material offers some benefits versus calcium hydroxide: It is mechanically stronger,

less soluble and produces tighter seals (Pradelle-Plasse et al. 2009). This qualifies it for avoiding three major drawbacks of calcium hydroxide, i.e. material resorption, mechanical instability and the resultant failure of preventing microleakage.

In contrast to the first recommendation of the manufacturer when Biodentine™ was launched, in the present case report Biodentine™ was used for direct pulp capping, replacement of the dentin layer and of the enamel layer with a composite restoration was performed during the same appointment. This treatment option offers several advantages: for successful direct pulp capping it is important to seal the cavity against bacterial invasion in a one-stage procedure (Duda and Dammaschke 2009, Dammaschke et al. 2010). While there is extensive evidence documenting that composite fillings are leak-proof, few pertinent data are available for Biodentine™ yet. Another argument against the two-stage procedure is the uncertain cooperativeness of patients: will or will they not show up for a second visit (Damaschke 2010)? Add to all this that the inevitable repeated cavity preparation during the second visit exposes the pulp tissue, already damaged by prior direct capping, to more stress. This can be avoided by a single-stage approach. When opting for this one visit approach it is, however, important to wait for Biodentine™ to set (about 12 to 15 minutes after mixing) before proceeding with the restorative treatment. The appearance of the Biodentine™ surface will

change from glossy to matt. Furthermore, it is important not only to apply Biodentine™ in area of the pulp perforation but to replace the whole missing dentin volume of the cavity. During the setting time the cement should not be prepared with rotating instruments and should not come into contact with water. It should rather be applied into the cavity with cement pluggers using light pressure. Excessive pressure or exaggerated trimming and polishing may disrupt the crystalline structure of Biodentine™ with resultant loss of material strength. Hence, the use of self-etching dentin adhesives may be favorable to avoid an etching with phosphoric acid and rinsing with water of the Biodentine™ surface.

It goes without saying that a follow-up time of six months is too short for evaluating the long-term success of a capping material. More long-term clinical studies are, therefore, needed for a definitive evaluation of Biodentine™.

Conclusion

Biodentine™ is an interesting and promising product, which has the potential of making major contributions to maintaining pulp vitality in patients judiciously selected for direct pulp capping. The single-stage approach in pulp capping simplifies and improves the clinical use of Biodentine™.



Dr Till Dammaschke, Assistant professor, DDM

Department of Operative Dentistry
Albert-Schweitzer-Campus 1, building W30
Waldeyerstr. 30 - 48149 Münster - Germany

Phone +49-251-8347035 - Fax +49-251-8347037 - tillda@uni-muenster.de

Studied dentistry at the University of Göttingen (Germany). He has been affiliated with the Department of Operative Dentistry at the University of Münster (Germany) since 1994 and was appointed senior resident in 1998. His research paper on direct capping earned him full teaching credentials in 2008. Aside from the maintenance of pulp vitality, he has focused on studying novel excavation techniques and endodontics.

References

1. Barnes IM, Kidd EA. Disappearing Dycal. *Br Dent J* 1979;147:111.
2. Baume LJ, Holz J. Long term clinical assessment of direct pulp capping. *Int Dent J* 1981;31:251-260.
3. Borges RP, Sousa-Neto MD, Varsiani MA, Rached-Júnior FA, De-Deus G, Miranda CES, Pécora JD (2011) Changes in the surface of four calcium silicate-containing endodontic materials and an epoxy resin-based sealer after a solubility test. *Int Endod J* doi: 10.1111/j.1365-2591.2011.01992.x [Epub ahead of print].
4. Boukpepsi T, Septier D, Goldberg M. VI-2-2-2 Animal studies. In: Goldberg M (ed.) *Biocompatibility or cytotoxic effects of dental composites*. Coxmoor, Oxford 2009. p 200-203.
5. Cox CF, Sübay RK, Ostro E, Suzuki S, Suzuki SH. Tunnel defects in dentinal bridges. Their formation following direct pulp capping. *Oper Dent* 1996;21:4-11.
6. Dammaschke T, Leidinger J, Schäfer E. Long-term evaluation of direct pulp capping-treatment outcomes over an average period of 6.1 years. *Clin Oral Investig* 2010;14:559-567.
7. Dammaschke T. Direct pulp capping. *Dentist* 2011;27(8):88-94.
8. Dammaschke T. Direkte Überkappung oder schrittweise Kariesexkavation? Eine aktuelle Übersicht. *Quintessenz* 2010;61:677-684.
9. Duda S, Dammaschke T. Die direkte Überkappung – Voraussetzungen für klinische Behandlungserfolge. *Endodontie* 2009;18:21-31.
10. Duda S, Dammaschke T. Maßnahmen zur Vitalerhaltung der Pulpa. Gibt es Alternativen zum Kalziumhydroxid bei der direkten Überkappung? *Quintessenz* 2008;59:1327-1334, 1354.
11. Gandolfi MG, van Lunduyt K, Taddei P, Modena E, van Meerbeek B, Prati C (2010) Environmental scanning electron microscopy connected with energy dispersive X-ray analysis and Raman techniques to study ProRoot Mineral Trioxide Aggregate and calcium silicate cements in wet conditions and in real time. *J Endod* 36, 851-857.
12. Goracci G, Mori G. Scanning electron microscopic evaluation of resin-dentin and calcium hydroxide-dentin interface with resin composite restorations. *Quintessence Int* 1996;27:129-135.
13. Hørsted P, Sandergaard B, Thylstrup A, El Attar K, Fejerskov O. A retrospective study of direct pulp capping with calcium hydroxide compounds. *Endod Dent Traumatol* 1985;1:29-34.
14. Laurent P, Aubut V, About I. VI-2-2-1 Development of a bioactive Ca₃SiO₅ based posterior restorative material (Biodentine™). In: Goldberg M (ed.) *Biocompatibility or cytotoxic effects of dental composites*. Coxmoor, Oxford 2009. p 195-200.
15. Laurent P, Camps J, de Méo M, Déjou J, About I. Induction of specific cell responses to a Ca₃SiO₅-based posterior restorative material. *Dent Mater* 2008;24:1486-1494.
16. Pradelle-Plasse N, Tran X-V, Colon P. VI-2-1 Physico-chemical properties. In: Goldberg M (ed.) *Biocompatibility or cytotoxic effects of dental composites*. Coxmoor, Oxford 2009. p 184-194.
17. Schröder U. Effects of calcium hydroxide-containing pulp-capping agents on pulp cell migration, proliferation, and differentiation. *J Dent Res* 1985;64(Spec Iss):541-548.
18. Schröder U. Evaluation of healing following experimental pulpotomy of intact human teeth and capping with calcium hydroxide. *Odontol Revy* 1972;23:329-340.
19. Torneck CD, Moe H, Howley TP. The effect of calcium hydroxide on porcine pulp fibroblasts in vitro. *J Endod* 1983;9:131-136.



Personal Clinical Experience with Biodentine™

Docent MU Dr. Lenka Roubalíková, PhD
Faculty of Medicine, Masaryk University
Private dental practice, Brno, Czech Republic

Introduction

We are currently witnessing extensive dynamic developments in dentistry, and endodontics is no exception. Mechanical systems with nickel-titanium root canal instruments, the surgical microscope, endodontic ultrasound, modern root canal filling techniques, as well as apical microsurgery, open up a wide range of possibilities for dental practitioners specializing in endodontics. There have also been significant advances in the management of endodontic treatment complications and in methods of maintaining dental pulp vitality. Calcium hydroxide, introduced to modern-day dentistry in the late 19th century by Hermann, continues to hold on to its important position. The disadvantages of calcium hydroxide are resorbability, difficult application and the impossibility of obtaining a hermetic seal. The Pro-Root® MTA material (Maillefer, Switzerland) represented a significant progress in the area of management of endodontic treatment complications, especially root perforations, as well as other difficult situations, such as endodontic treatment of permanent teeth with incomplete development or with resorption. However, the limiting factors in the use of this material are

uncomfortable application, tooth discoloration and the uncertain outcome of dental pulp capping (apparently related to the consistency of the material and the way it is handled). This is why the dental community showed great interest in the possibility of using the bioactive material Biodentine™ (Septodont, France).

Basic information

Biodentine™ consists of a powder and a liquid. The core of the powder is tricalcium silicate; this is mixed with the liquid, the main component of which is an aqueous solution of calcium chloride. Of interest are Biodentine™'s mechanical properties, which resemble those of natural dentin, its good bonding to dentin and hermetic sealing of margins.

Its current indications are defined as follows:

In the area of the dental crown

- Temporary enamel replacement
- Permanent dentine replacement
- Treatment of deep carious lesions using the sandwich technique

- Treatment of deep cervical and radicular lesions
- Pulp capping after exposure
- Pulpotomy

In the area of the dental root

- Treatment of root perforations
- Treatment of perforations in the furcation area
- Treatment of perforating internal resorptions
- Repair of external resorptions
- Apexification
- Retrograde root canal filling (during apical surgery)

The use of Biodentine™ is not recommended in the following situations:

- Build-up of a large loss of tooth substance
- Build-ups in an esthetically exposed section of the dentition
- Treatment of teeth with irreversible pulpitis

The material comes in capsules; the manufacturer provides a detailed description of the preparation method. This consists of opening the capsule, adding the liquid dropwise to the powder, closing the capsule and mechanically mixing for approx. 30 s at a speed of around 4200 rpm. The material is applied using routine filling instruments; an amalgam gun can also be used.

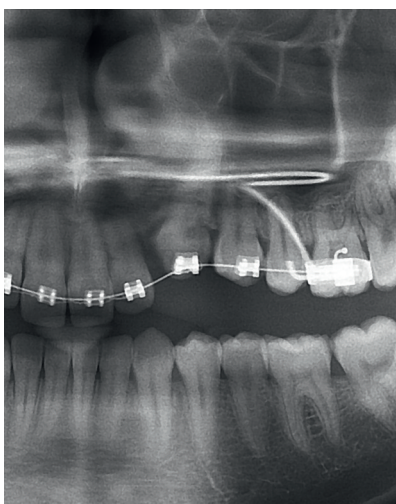


Fig. 1a: X-ray of a patient with an external resorption on tooth #23 - section from a panoramic X-ray.

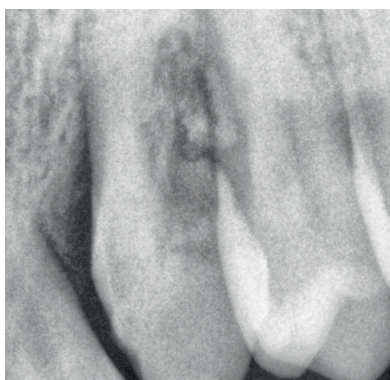


Fig. 1b: Intraoral X-ray before treatment.

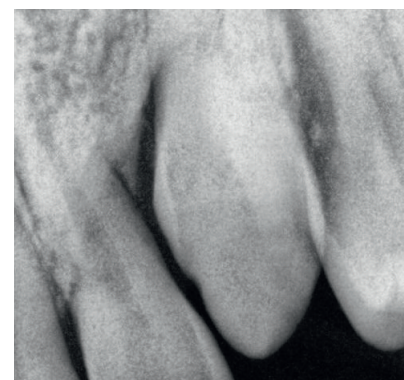


Fig. 1c: Intraoral X-ray following treatment with Biodentine

Preparation

To facilitate comfortable handling of the material and to achieve good-quality bonding to dental tissue, exactly 5 drops have to be added to the powder. Failure to do so results in an extremely dry material. An excessive amount of liquid should be avoided, as the material then has a runny consistency and features a longer setting time. Correctly mixed material must have a creamy consistency. The manufacturer recommends a dry operating field, i.e. the use of dental dam. This cannot always be used (e.g. during apical surgery) and is not absolutely essential in all cases, e.g. in the maxilla. However, good relative drying and a clean treated area are a necessary prerequisite. The material is radiopaque.

Case report

1. Treatment of a resorption

Biodentine™ was used in one case of external resorption which affected the coronal half of the root and extended far enough to expose the pulp. The tooth was an ankylotic upper permanent canine after unsuccessful

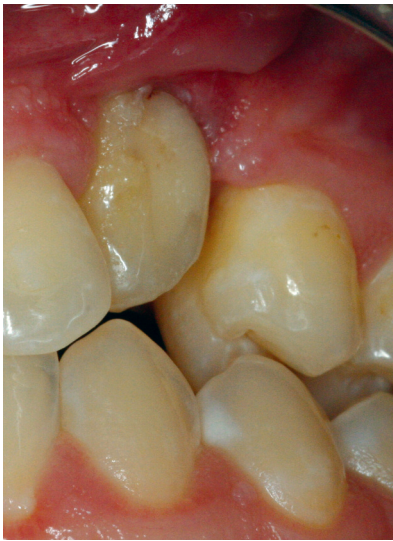

Fig. 2a: Situation before treatment - tooth #23 with external resorption, the lacuna is partially filled with glass-ionomer cement

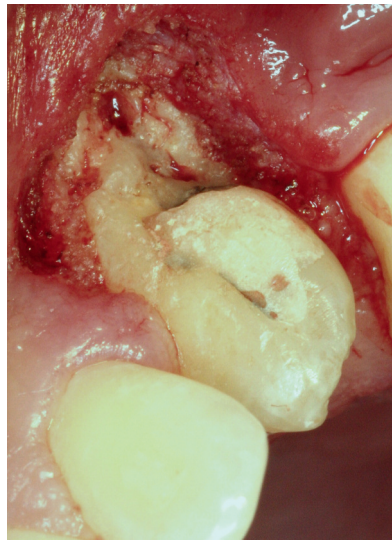

Fig. 2b: Condition after exposure of the resorption lacuna - the mucoperiosteum is removed using an erbium, chromium (Er, Cr): YSGG laser

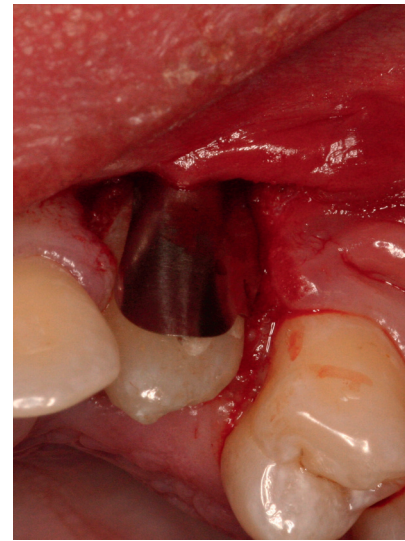


Fig. 2c: Using a matrix (Ultradent, USA) to allow the material to set undisturbed

orthodontic treatment. The mucoperiosteal flap was lifted to expose the resorption lacuna and Biodentine™ was applied; the material was protected by a matrix (Ultradent, USA) while setting. The material was then covered with a protective coating (G-Coat, GC, Japan). Once healed, the tooth was treated with an indirect veneer from composite plastic (Chromasit, Ivoclar-Vivadent, Lichtenstein) to correct its shape and position. The patient has been complaint-free for 2 months. *Fig. 1a – 1c, 2a – 2e.*

2. Treatment of perforations

Biodentine™ was used in 4 cases of root perforation. In 2 cases the perforation was in the coronal third of the root - a maxillary lateral incisor and a maxillary first premolar. The root canal was always prepared and obturated and then the perforation canal was filled using a spreader and a plugger. More than 4 months have elapsed since the treatment in all the cases; the patients are complaint-free, there is no discoloration of the dental crown. Next, Biodentine™ was used for the treatment of furcation perforations in 2 patients, who are now 2 and 4 months post treatment. The patients are complaint-free. There has been no discoloration. *Fig. 3a - c.*

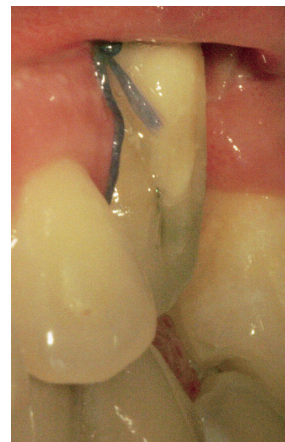

Fig. 2d: The lesion after filling with Biodentine, covered with G-Coat protective coating (GC, Japan)

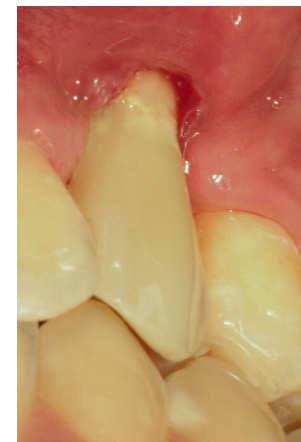


Fig. 2e: Condition after treatment with an indirect composite veneer (Chromasit, Ivoclar-Vivadent, Lichtenstein)

3. Treatment of caries close to the dental pulp

Biodentine™ was used to cap the dental pulp in 3 cases of caries penetrating into the dental pulp. The longest time interval has been 5 months, the shortest 1 month. From the clinical point of view, there have been no clinical signs of dental pulp inflammation, the material remains in situ, the patients are complaint-free, in one case Biodentine™ has already been covered with composite material. An X-ray check of the cavity filling is highly advisable. *Fig. 4 and Fig. 5a, b.*

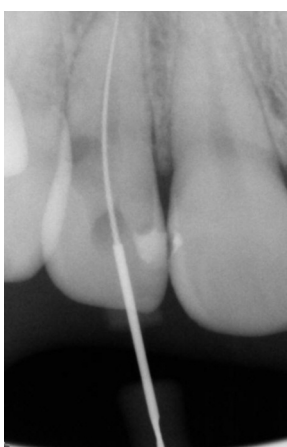

Fig. 3a: Tooth #12 with an iatrogenic perforation and a gutta-percha point inserted into the root canal

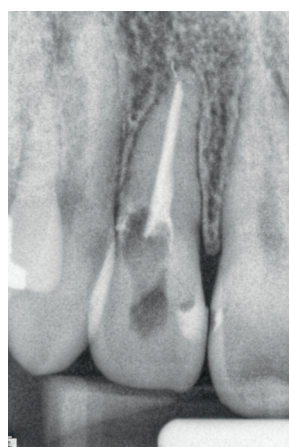


Fig. 3b: Tooth #12 after root canal filling

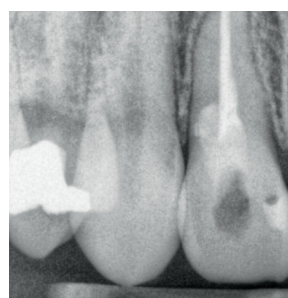


Fig. 3c: The tooth after filling of the perforation canal with Biodentine™

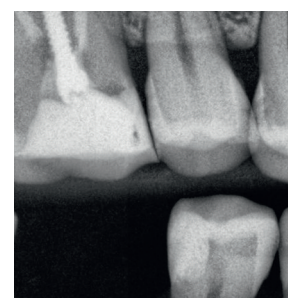


Fig. 4: A carious cavity in tooth #45 filled with Biodentine on an intraoral X-ray (bitewing projection)

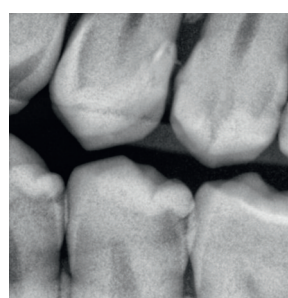


Fig. 5a: Caries close to the dental pulp in tooth #35 on an intraoral X-ray (bitewing projection)

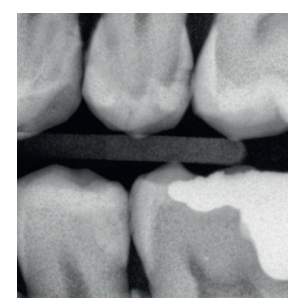


Fig. 5b: Situation after filling of the lesion with Biodentine on an intraoral X-ray (bitewing projection)

Conclusion and recommendations for practice

Biodentine™ appears to be a promising material for the treatment of previously difficult-to-manage endodontic situations. Compared to an MTA material, Biodentine™ is easier to work with, there is no discolouration of the dental crown, the material can be exposed to the oral

cavity environment for a relatively long period of time (up to 6 months) and it can be covered with an adhesive material without any problems. Results obtained with dental pulp capping can be interesting. We will continue to report on further experience.



Dr. Lenka Roubalíková, Ph.D. Associated Professor

Graduation at Medical Faculty of Masaryk University, Brno, Czech Republic
Email: lenka.roubalikova@tiscali.cz

Habilitation 2004 at the Medical Faculty of Masaryk University, Brno, Czech Republic. She has been affiliated with Department of Operative Dentistry at Masaryk University in Brno (part time teacher), Other activities: A chairman of the scientific committee of the congress Prague Dental Days, scientific secretary of the Czech endodontic Society, member of ESE, Member of the Czech Periodontal Society. She is an author of 70 papers (articles and chapters in books) and held more than 100 lectures in the Czech Republic and abroad. She runs also her own practice.

References

Dammaschke T. „Biodentine™ – A New Bioactive Cement for Direct Pulp Capping”

A Four Year Retrospective Case Study in the Use of N'Durance® Composite

Dr Holli Riter, Assistant Professor, DDS
University of Loma Linda, California, USA
HRiter@llu.edu

Introduction

Finding a long lasting and esthetically pleasing composite for anterior restorations has long been a challenge in dentistry. Recently, Septodont Inc. (Louisville, CO) introduced N'Durance® composite as a solution to this challenge. N'Durance® composite resin combines a newly developed monomer with nano-sized filler particles to create a composite that is structurally and functionally strong, while having the esthetic qualities such as high polishability that are needed for anterior esthetic zone treatment. In this case study, restorations were placed in a patient desiring a diastema closure. The material has been observed over 4 years at this point. The results so far have been highly esthetically pleasing.

Case report

A 26 year-old woman presented with a diastema between teeth #10 and 11 that she reports she was very self conscious about. The patient had otherwise healthy dentition and gingival

conditions. The patient was not interested in orthodontic procedures to close the space. She was informed of her treatment options, including porcelain laminate veneers. It was mutually decided that a diastema closure with resin bonding using the N'Durance® composite was the preferred method to address this diastema, since composite bonding required very little removal of tooth structure, which was an important factor to this patient.

The diastema between #10 and 11 was approximately 1.5 mm wide at the closest distance between the two teeth (*fig. 1*). No anesthetic was used as this procedure was minimally invasive. A course grit diamond rotary

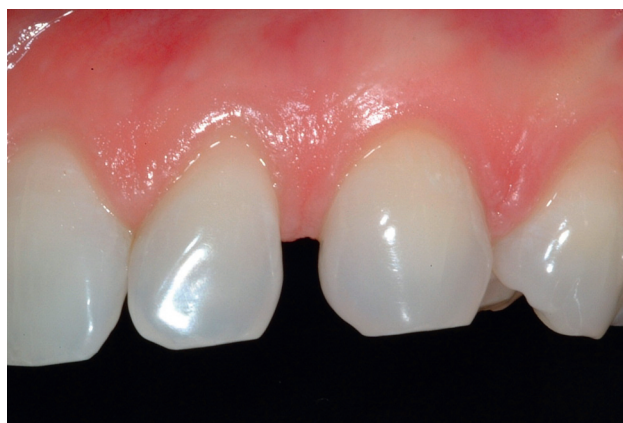

Fig. 1

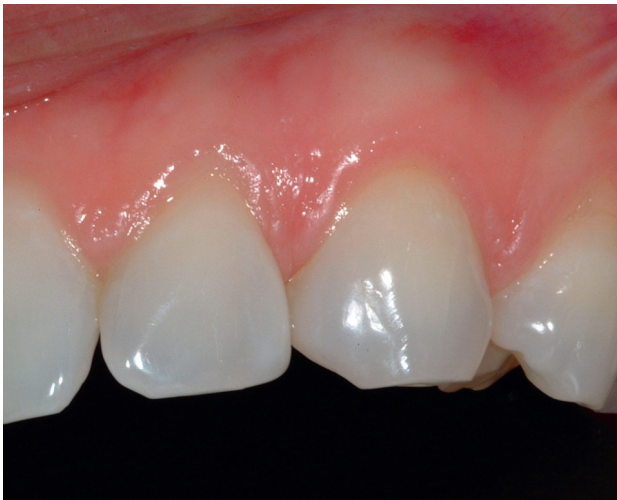

Fig. 2

instrument (Neo Diamond, Kennesaw, GA) was used to roughen the tooth structure on the distal of #10 and the mesial of #11. The preparations were acid etched with a 37.5% phosphoric etching gel (Kerr, Orange, CA), for 20 seconds, then thoroughly rinsed with water. The excess water was removed. The preparations were bonded with Opti-Bond Solo (Kerr, Orange, CA) and light cured for 20 seconds according to manufacturer's recommendations. They were then filled with N'Durance® resin composite with a 1-2 mm incremental technique, curing each increment for 30 seconds. The curing light (with a minimum radiance of 500 mW/cm²) was held approximately 1 mm away from the tooth surface during the light activation. The restorations were finished with carbide finishing rotary instruments (Brasseler USA, Savannah, GA) and polished with OptiDiscs (Kerr, Orange, CA), Jiffy Polishing Points and Cups (Ultradent, Salt Lake City, UT) and Jiffy Composite Polishing Brushes (Ultradent, Salt Lake City, UT). The shade used for the distal of #10 was a layered combination of Bleach White (BW) and Incisal (INC), and only Incisal (INC) shade was used for the mesial of #11. The patient had a very light initial shade, as well as a significant translucent quality to the teeth. Because of this translucency, the Incisal (INC) shade was an excellent match. The two weeks post placement result is shown in *Figure 2*. The patient was extremely happy with the results. A post-

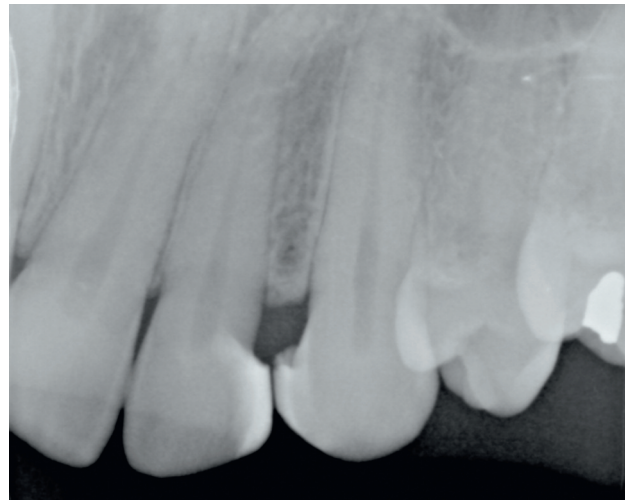


Fig. 3

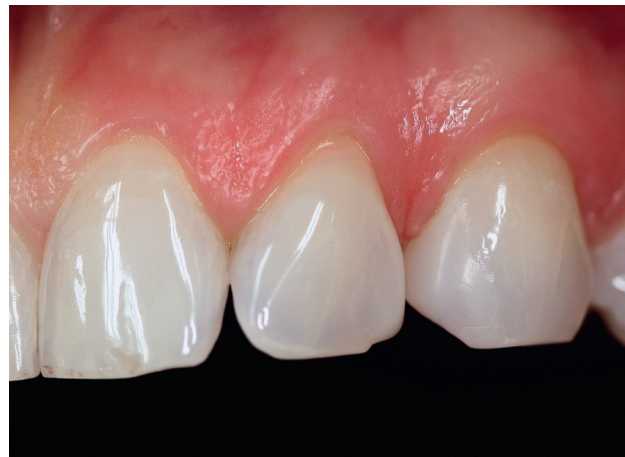

Fig. 4

placement radiograph was taken. The high opacity of N'Durance® resin makes it easy for the dentist to identify (*Fig. 3*). This is an important factor in the diagnosis of recurrent decay, and the correct reading of the radiographs.

This patient has now been evaluated four years after the initial placement of the N'Durance® resin. The patient still is extremely happy with her restorations that have shown no signs of significant marginal changes or overall color changes. There is no staining on the resin, neither at the body nor along the margins. Most impressively, the polish is still very high after four years in the patient's mouth. No re-polishing has been recommended or deemed to be needed. *Figure 4* shows the patient's restorations at four years after the initial placement.

Conclusion

The N'Durance® resin composite in this case has shown very high esthetic qualities, as well as high strength and functional qualities. It appears

to be an excellent choice to address the needs of dentists and their patients who have high demands for function in the esthetic zone.



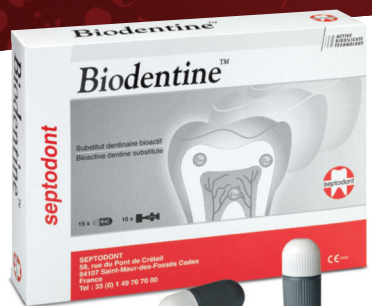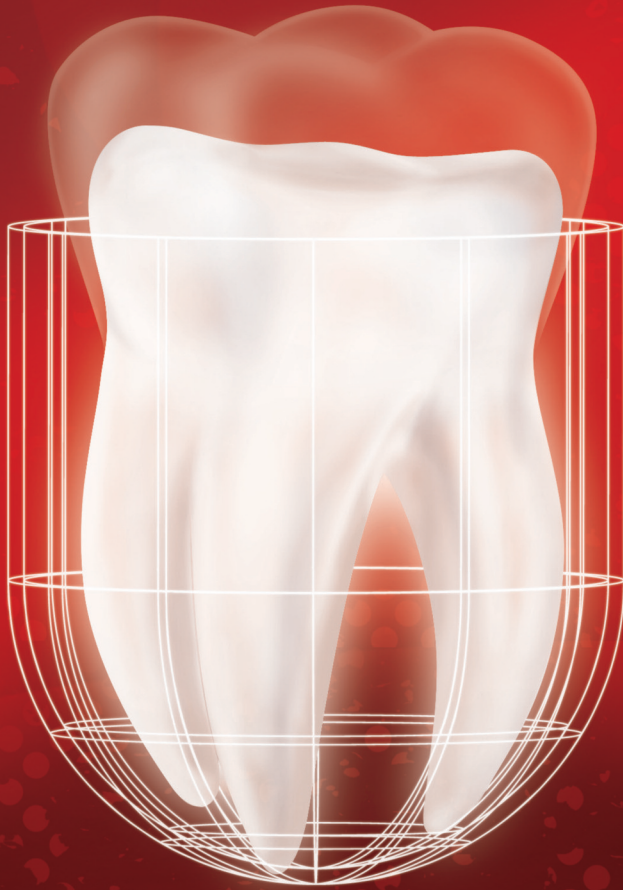Dr Holli Riter, Assistant Professor, DDS

University of Loma Linda, California, USA
HRiter@llu.edu

Holli Riter is a full time faculty member at Loma Linda University School of Dentistry. She graduated from the School of Dentistry in 1998 and worked for several years in private practice. She joined the faculty full time as an assistant professor in 2005, and later joined the Center for Dental Research in 2007. She enjoys both working with students as they learn dentistry and working in dental research, with a focus on esthetic materials. She is an active member of the International and American Association of Dental Research, the Academy of Cosmetic Dentistry, and the Academy of Operative Dentistry.

Biodentine™

The first and only dentin in a capsule



ACTIVE
BIOSILICATE
TECHNOLOGY

As the **first all-in-one** biocompatible and bioactive **dentin substitute**, Biodentine™ fully replaces dentin wherever it's damaged.

Biodentine™ helps the remineralization of dentin, preserves the pulp vitality and promotes pulp healing. It replaces dentin with similar biological and mechanical properties.


Improving on **Biodentine™** clinical implementation, you can now bond the composite onto Biodentine™ in the same visit and perform the **full restoration in a single session**.

To enjoy the clinical benefits of the first and only dentin in a capsule, ask your dental distributor for Biodentine™.



Learn more with
the Biodentine™ brochure





The Dental Pharmaceutical Company

INNOVATIVE, SAFE AND EFFECTIVE SOLUTIONS FOR DENTISTRY WORLDWIDE